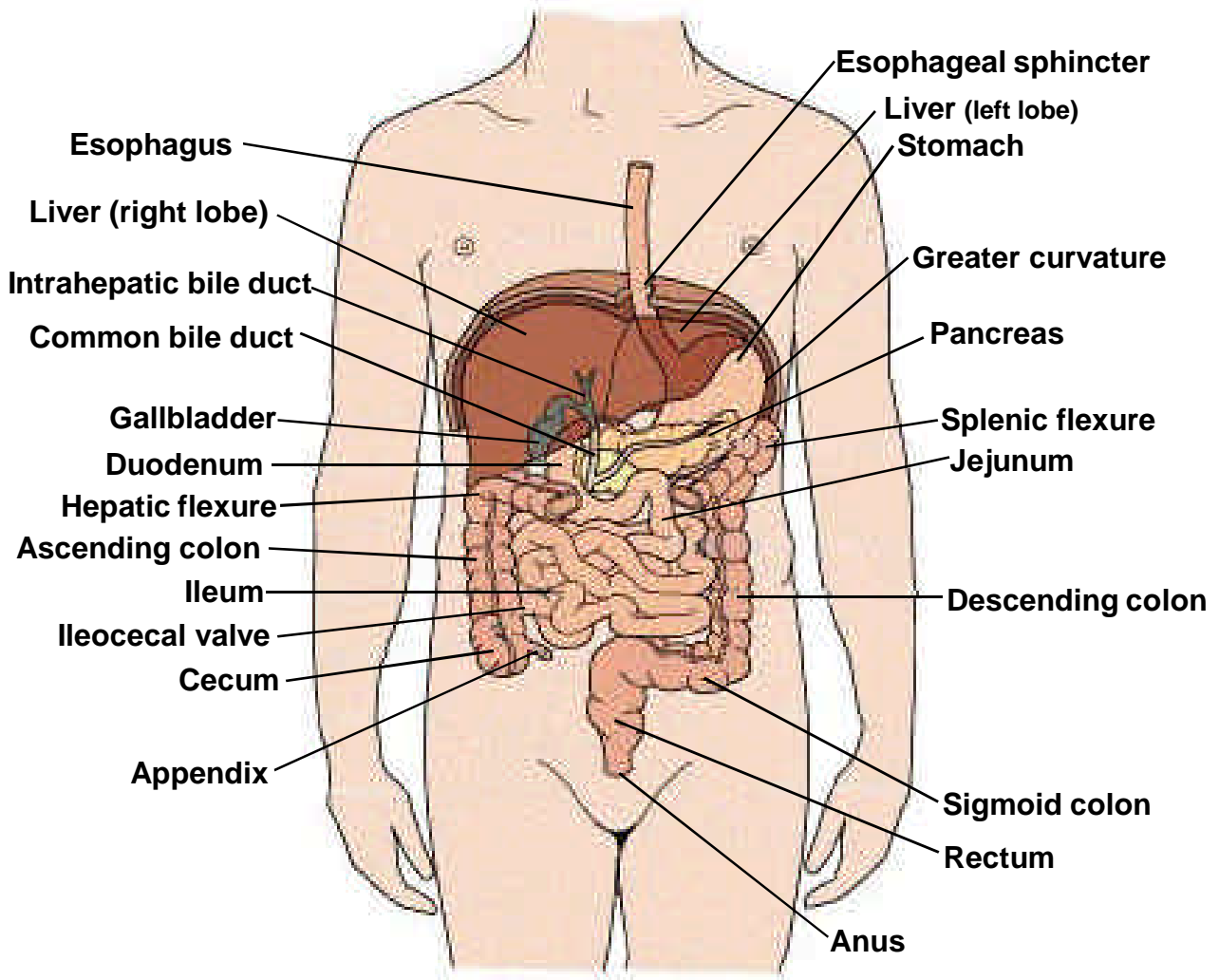
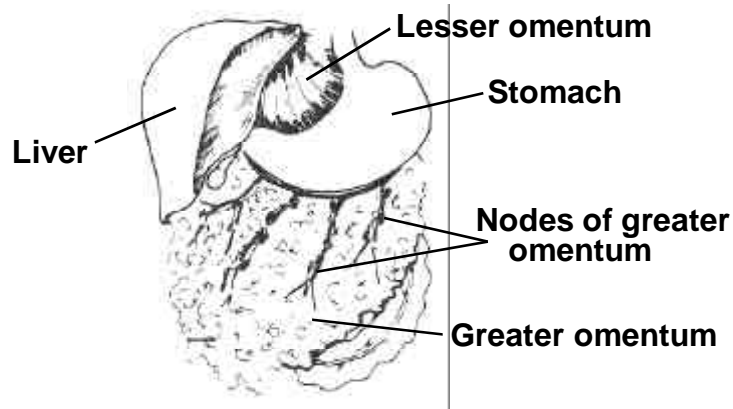


## ANATOMIC DRAWINGS OF THE DIGESTIVE SYSTEM

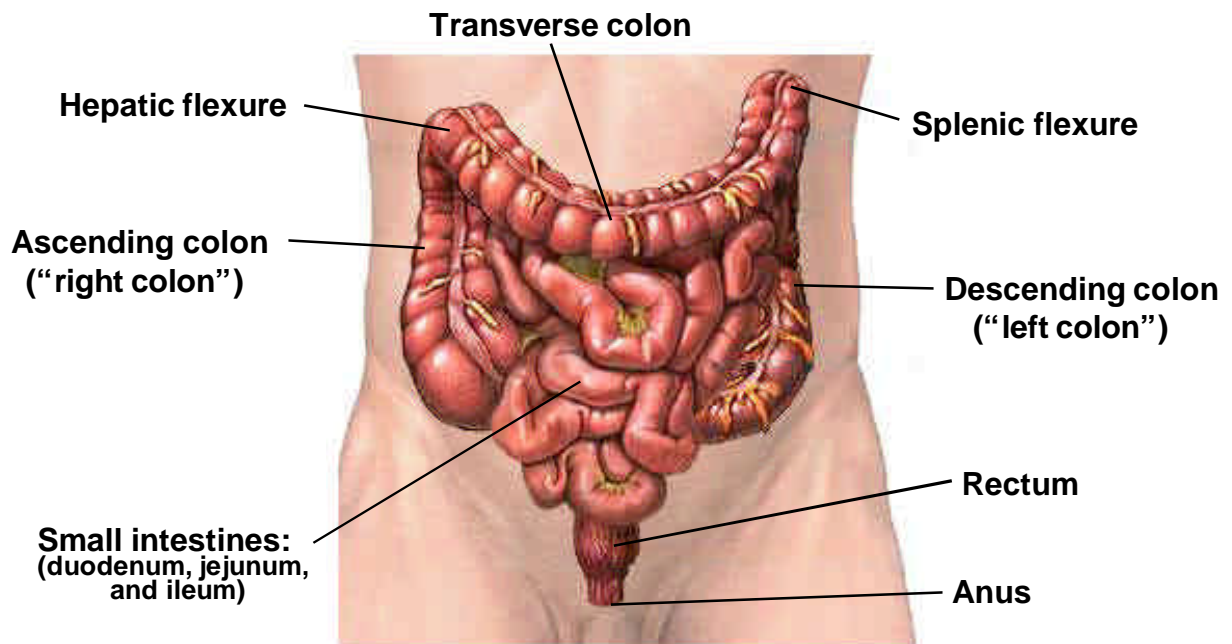


**THE ALIMENTARY CANAL**



**LESSER AND GREATER OMENTUM**

## ANATOMIC DRAWINGS OF THE DIGESTIVE SYSTEM



### THE INTESTINES

**DIGESTIVE SYSTEM SITES  
TABLE OF ANATOMIC STRUCTURES**

| PRIMARY SITE         | MUCOSA      |        |                |            | SUB-MUCOSA | MUSCULARIS | SUB-SEROSAL TISSUES <sup>1</sup> | Serosa <sup>2</sup> | OUTSIDE THE SEROSA <sup>3</sup>        |
|----------------------|-------------|--------|----------------|------------|------------|------------|----------------------------------|---------------------|--|
|                      | Epi-thelium |        | Lamina Propria | Muscularis |            |            |                                  |                     |  |
| Esophagus (C15.)     | Yes         | B      | Yes            | Yes        | Yes        | Yes        | See note 4.                      | No                  | See note 4.                            |
| Stomach (C16.)       | Yes         | S      | Yes            | Yes        | Yes        | Yes        | No                               | Yes                 | Greater and lesser omentum             |
| Sm. Intestine (C17.) | Yes         | E<br>M | Yes            | Yes        | Yes        | Yes        | No                               | Yes                 | Mesentery of small intestine           |
| Colon (C18.)         | Yes         | E      | Yes            | Yes        | Yes        | Yes        |                                  | Yes                 | :                                      |
| .0 Cecum             | Yes         | N      | Yes            | Yes        | Yes        | Yes        | Yes                              | Yes                 | :                                      |
| .1 Appendix          | Yes         | T      | Yes            | Yes        | Yes        | Yes        | Yes                              | Yes                 | :                                      |
| .2 Ascending         | Yes         | M      | Yes            | Yes        | Yes        | Yes        | No                               | See note 5.         | :                                      |
| .3 Hepatic flex.     | Yes         | E      | Yes            | Yes        | Yes        | Yes        | Yes                              | Yes                 | Mesenteric or pericolic fat            |
| .4 Transverse        | Yes         | M      | Yes            | Yes        | Yes        | Yes        | Yes                              | Yes                 | :                                      |
| .5 Splenic flex.     | Yes         | B      | Yes            | Yes        | Yes        | Yes        | Yes                              | Yes                 | :                                      |
| .6 Descending        | Yes         | R      | Yes            | Yes        | Yes        | Yes        | No                               | See note 5.         | :                                      |
| .7 Sigmoid           | Yes         | A      | Yes            | Yes        | Yes        | Yes        | Yes                              | Yes                 | :                                      |
| .8 Overlapping       | Yes         | N      | Yes            | Yes        | Yes        | Yes        |                                  | Yes                 | :                                      |
| .9 Colon, NOS        | Yes         | E      | Yes            | Yes        | Yes        | Yes        |                                  |                     | :                                      |
| Rectosigmoid (C19.9) | Yes         |        | Yes            | Yes        | Yes        | Yes        | Yes                              | Yes                 | Mesenteric or pericolic/perirectal fat |
| Rectum (C20.9)       | Yes         |        | Yes            | Yes        | Yes        | Yes        | No                               | No                  | See note 6.                            |

- 1 Subserosal tissues include fat and flesh between the muscularis and the serosa.
- 2 Serosa is also called mesothelium and visceral peritoneum. For the stomach and small intestine, serosa is also referred to as tunica serosa. The term “serosa” is sometimes generically used to include both the serosa and the subserosa, and therefore, the clinician should be consulted to determine if the use of “serosa” includes the subserosa also.
- 3 Mesenteric fat is also called pericolic fat.
- 4 The tissue outside the muscularis of the esophagus is composed of fibrous connective tissue and referred to as adventitia.
- 5 Anterior and/or medial aspects, but not lateral.
- 6 Referred to as perirectal tissue.

## **DISTINGUISHING “IN SITU” AND “LOCALIZED” TUMORS FOR THE DIGESTIVE SYSTEM**

Careful attention must be given to the use of the term “confined to mucosa” for the esophagus, stomach, small intestine, colon and rectum.

Historically, carcinomas described as “confined to mucosa” have been coded as localized. In order to provide greater specificity and to rule out the possibility of classifying noninvasive tumors in this category, abstractors should determine:

- 1) if the tumor is confined to the epithelium, in which case it is in situ, **OR**
- 2) if the tumor has penetrated the basement membrane to invade the lamina propria, in which case it is localized and is coded to invasion of the lamina propria.

The mucosa of the digestive tract consists of:

The **EPITHELIAL LAYER** borders on the lumen. It contains no blood vessels or lymphatics.

The **BASEMENT MEMBRANE**, a sheet of extracellular material, functions as a filtration barrier and a boundary involved in generating and maintaining tissue structure.

The **LAMINA PROPRIA**, composed of areolar connective tissue, contains blood vessels, nerves, and, in some regions, glands. Once tumor has broken through the basement membrane into the lamina propria, it can spread by way of the lymphatics and blood vessels to other parts of the body.

The **MUSCULARIS MUCOSAE** is a thin layer of smooth muscle fibers. It is found in the wall of the digestive tract from the esophagus to the anal canal.

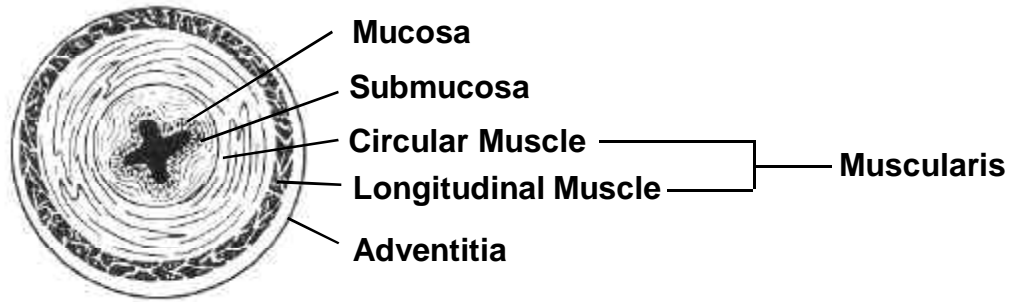
The **SUBMUCOSA** is a thick layer of either dense or areolar connective tissue. It contains blood vessels, lymphatic vessels, nerves, and, in some regions, glands.

The **MUSCULARIS PROPRIA** is a double layer of muscle tissue in most of the digestive tract; it constitutes the wall of the organ.

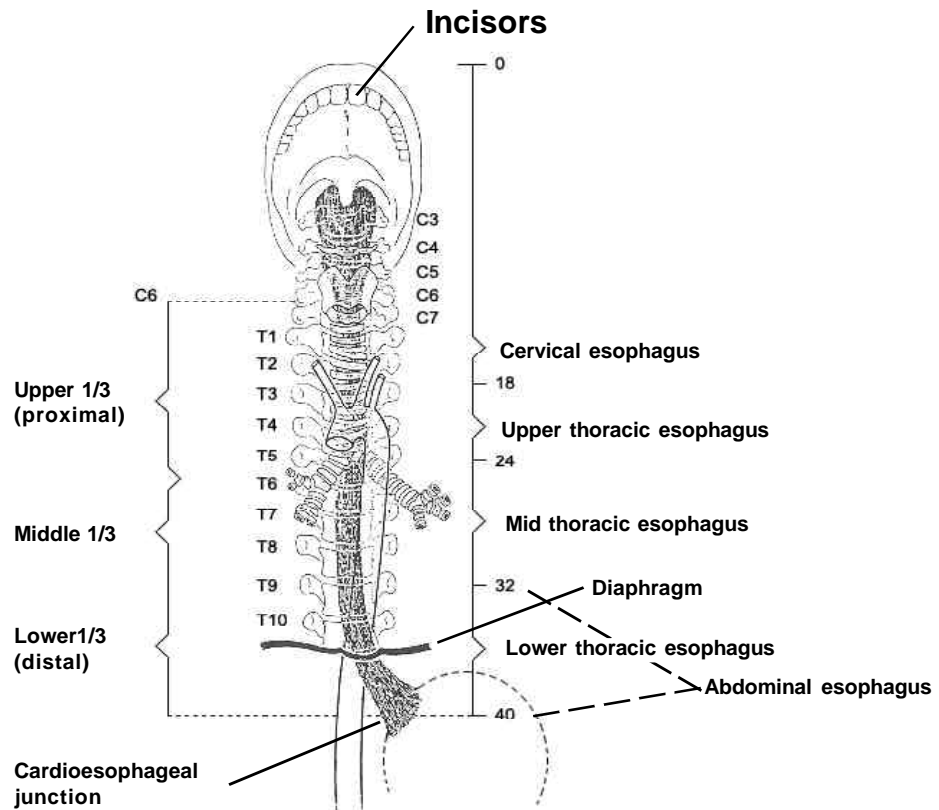
The **SEROSA**, the outermost layer covering most of the digestive tract, is a single layer of squamous epithelial cells, part of the visceral peritoneum. Just inside the serosa (mesothelium), and sometimes considered part of the serosa, is a layer of connective tissue called the subserosa. The serosa and subserosa are present only in the peritonealized portions of the digestive tract. For the esophagus and in the rectum below the peritoneal reflection, there is no serosa. For the esophagus, the connective tissue of surrounding structures merges with the connective tissue of the esophagus and is called **ADVENTITIA**.



## ANATOMIC DRAWINGS OF THE ESOPHAGUS



## CROSS SECTION OF ESOPHAGUS



## THE ESOPHAGUS

## **ESOPHAGUS**

C15.0-C15.5, C15.8-C15.9

C15.0 Cervical esophagus

C15.1 Thoracic esophagus

C15.2 Abdominal esophagus

C15.3 Upper third of esophagus

C15.4 Middle third of esophagus

C15.5 Lower third of esophagus

C15.8 Overlapping lesion of esophagus

C15.9 Esophagus, NOS

Anatomic Limits of Esophagus:

**CERVICAL ESOPHAGUS (C15.0):** From the lower border of the cricoid cartilage to the thoracic inlet (suprasternal notch), about 18 cm from the incisors.

**INTRATHORACIC (including ABDOMINAL) ESOPHAGUS (C15.1-C15.5):**

Upper thoracic portion (C15.3): From the thoracic inlet to the level of the tracheal bifurcation (18-24 cm)

Mid-thoracic portion (C15.4): From the tracheal bifurcation midway to the gastroesophageal (GE) junction (24-32 cm).

Lower thoracic portion (C15.5): From midway between the tracheal bifurcation and the gastroesophageal junction to the GE junction, including the abdominal esophagus (C15.2) between 32-40 cm.

## **SUMMARY STAGE**

**0 In situ:** Noninvasive; intraepithelial

**1 Localized only**

Invasive tumor confined to:

Intramucosa, NOS

Lamina propria

Mucosa, NOS

Muscularis mucosae

Muscularis propria invaded

Submucosa

Localized, NOS

**2 Regional by direct extension only**

Adventitia and/or soft tissue invaded  
Esophagus is described as “FIXED”

Extension to:

**Cervical esophagus (including first 18 cm of upper esophagus):**

Blood vessel(s) (major):

Carotid artery

Jugular vein

Subclavian artery

Carina

Cervical vertebra(e)

Hypopharynx

Larynx

Trachea

Thyroid gland

**Intrathoracic:**

Lung via bronchus

Mediastinal structure(s)

Pleura

Rib(s)

Thoracic vertebra(e)

**Intrathoracic, upper or mid-portion, esophagus:**

Blood vessel(s) (major):

Aorta

Azygos vein

Pulmonary artery/vein

Vena cava

Carina

Diaphragm

Main stem bronchus

Trachea

**Intrathoracic, lower portion (abdominal), esophagus:**

Blood vessel(s) (major):

Aorta

Gastric artery/vein

Vena cava

Diaphragm

Stomach, cardia (via serosa)

**Continued on next page**



## ESOPHAGUS

C15.0-C15.5, C15.8-C15.9

### 3 Regional lymph node(s) involved only

REGIONAL Lymph Nodes (including contralateral or bilateral)

#### **Cervical only:**

Cervical, NOS:

Anterior deep cervical (laterotracheal) (recurrent laryngeal)

Internal jugular, NOS:

Deep cervical, NOS:

Upper, NOS:

Jugulodigastric (subdigastric)

Peri-/paraesophageal

Scalene (inferior deep cervical)#####

Supraclavicular (transverse cervical)#####

#### **Intrathoracic, upper thoracic or middle, only:**

Internal jugular, NOS:

Deep cervical, NOS:

Lower, NOS:

Jugulo-omohyoid (supraomohyoid)

Middle

Upper, NOS:

Jugulodigastric (subdigastric)

Intrabronchial:

Carinal (tracheobronchial) (tracheal bifurcation)

Hilar (bronchopulmonary) (proximal lobar) (pulmonary root)

Peritracheal

Left gastric (superior gastric):###

Cardiac (cardial)

Lesser curvature

Perigastric, NOS

Peri-/paraesophageal

Posterior mediastinal (tracheoesophageal)###

Superior mediastinal#####

#### **Intrathoracic, lower (abdominal), only:**

Left gastric (superior gastric):

Cardiac (cardial)

Lesser curvature

Perigastric, NOS

Peri-/paraesophageal

Posterior mediastinal (tracheoesophageal)

Regional lymph node(s), NOS

**4 Regional by BOTH direct extension AND regional lymph node(s) involved**

Codes (2) + (3)

**5 Regional, NOS**

**7 Distant site(s)/lymph node(s) involved**

Adjacent structures:

Cervical/upper esophagus:

Lung

Main stem bronchus

Pleura

Thoracic/middle esophagus:

Pericardium\*\*

Abdominal/lower esophagus:

Diaphragm fixed

Distant lymph node(s):

Celiac **for intrathoracic esophagus**

Cervical, NOS **for intrathoracic esophagus**

Para-aortic **for lower/abdominal esophagus only**

Scalene (inferior deep cervical) **for intrathoracic esophagus only**

Superior mediastinal **for cervical esophagus only**

Supraclavicular (transverse cervical node) **for intrathoracic only**

Other distant lymph node(s)

Further contiguous extension

Metastasis

**9 Unknown if extension or metastasis**

**Note:** Ignore intraluminal extension to adjacent segment(s) of esophagus or to cardia of stomach and code depth of invasion or extra-esophageal spread as indicated.

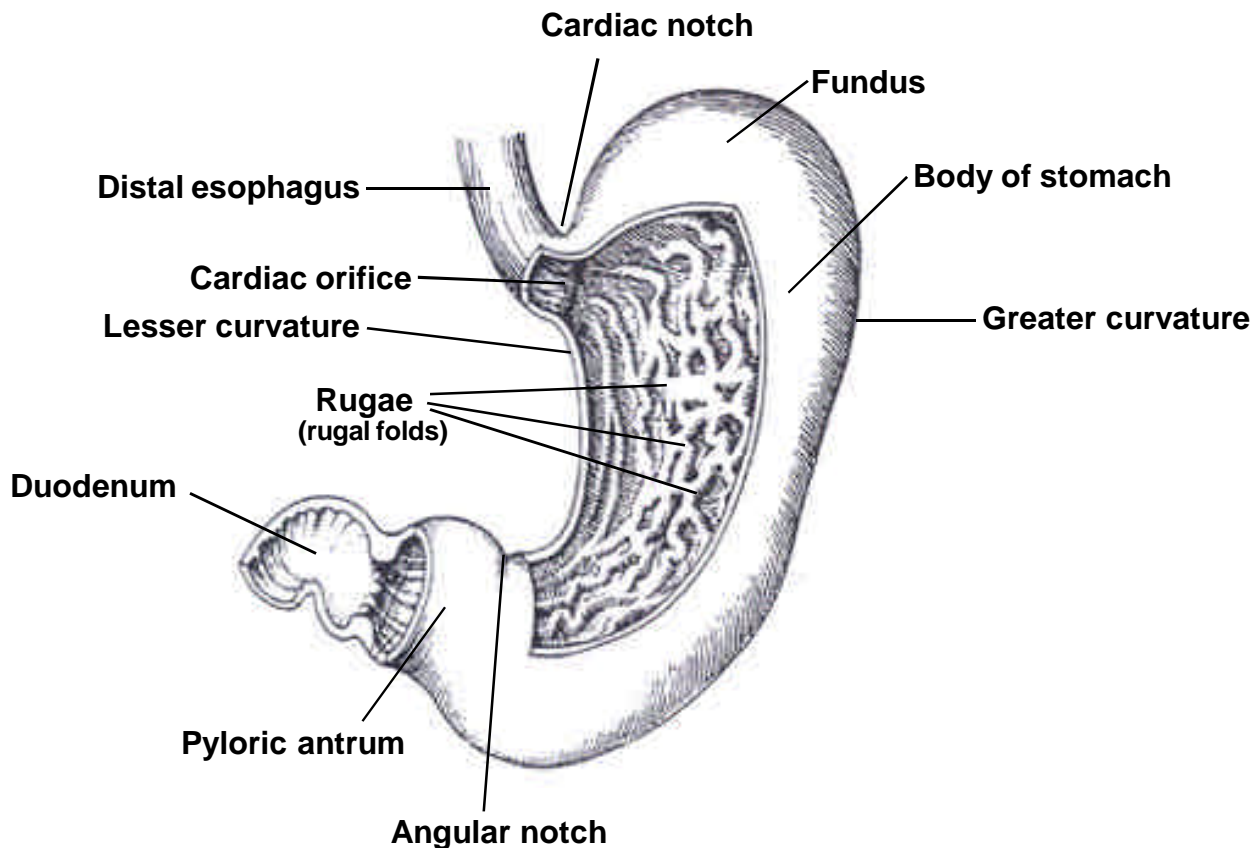
### Considered distant in Historic Stage

\*\* Considered regional in 1977 Summary Staging Guide

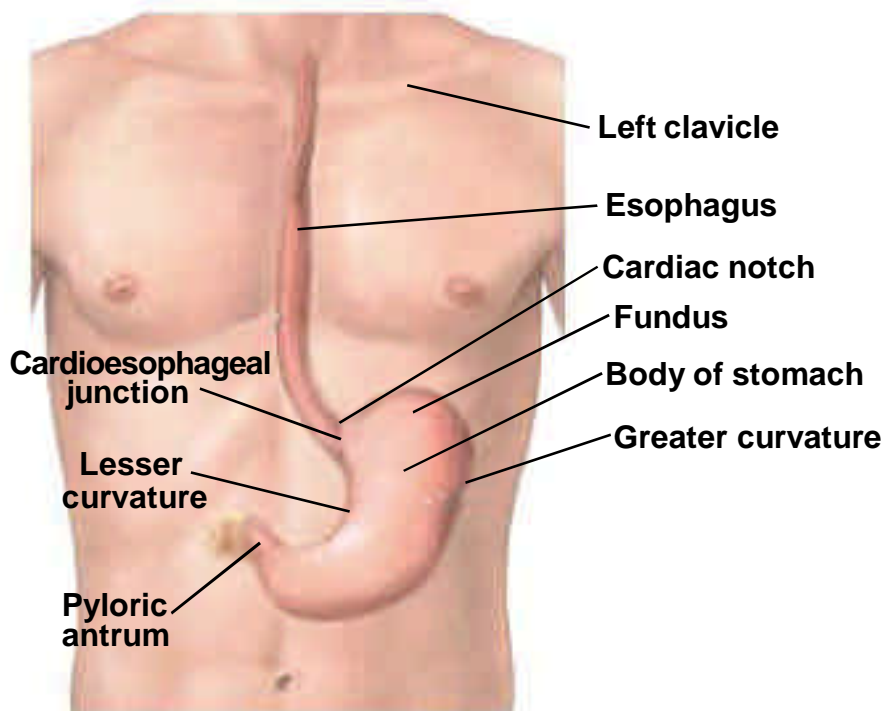
\*\*\* Considered distant in 1977 Summary Staging Guide



**ANATOMIC DRAWINGS OF THE STOMACH**



**THE STOMACH (WITH CUT-OUT)**



**THE ESOPHAGUS AND STOMACH**

## **STOMACH**

C16.0-C16.6, C16.8-C16.9

C16.0 Cardia, NOS

C16.1 Fundus of stomach

C16.2 Body of stomach

C16.3 Gastric antrum

C16.4 Pylorus

C16.5 Lesser curvature of stomach, NOS

C16.6 Greater curvature of stomach, NOS

C16.8 Overlapping lesion of stomach

C16.9 Stomach, NOS

## **SUMMARY STAGE**

**0 In situ:** Noninvasive; intraepithelial  
(Adeno)carcinoma in a polyp, noninvasive

### **1 Localized only**

Invasive tumor confined to:

Intramucosa, NOS

Lamina propria

Mucosa, NOS

Muscularis mucosae

Muscularis propria

Perimuscular tissue invaded

Polyp, NOS:

Head of polyp

Stalk of polyp

Submucosa (superficial invasion)

Subserosal tissue/(Sub)serosal fat

Extension through wall, NOS

Implants inside stomach

Intraluminal spread (only) to esophagus or duodenum<sup>###\*</sup>

Invasion through muscularis propria or muscularis, NOS

Linitis plastica (diffuse involvement of the entire stomach wall)<sup>\*\*</sup>

Localized, NOS

### **2 Regional by direct extension only**

Extension to:

Adjacent tissue, NOS

Connective tissue:

Gastric artery

Ligaments:

Gastrocolic

Gastrohepatic

Gastrosplenic

Code 2 continued on next page

**STOMACH**  
C16.0-C16.6, C16.8-C16.9

**2 Regional by direct extension only (continued)**

Omentum, NOS:  
    Greater  
    Lesser  
Perigastric fat  
Diaphragm  
Duodenum via serosa or NOS  
Esophagus via serosa  
Ileum  
Jejunum  
Liver  
Pancreas  
Small intestine, NOS  
Spleen  
Transverse colon including flexures  
  
Invasion of/through:  
    Mesothelium<sup>#</sup>  
    Serosa<sup>#</sup>  
    Tunica serosa<sup>#</sup>  
    Visceral peritoneum<sup>#</sup>

**3 Regional lymph node(s) involved only**

REGIONAL Lymph Nodes

Celiac <sup>\*\*\*\*##</sup>  
Hepatic <sup>\*\*\*\*##</sup>  
Left gastric (superior gastric), NOS:  
    Cardial  
    Cardioesophageal  
    Gastric, left  
    Gastropancreatic, left  
    Lesser curvature  
    Lesser omentum  
    Paracardial  
Pancreaticosplenic (pancreaticolienal)  
Perigastric, NOS  
Peripancreatic

**Code 3 continued on next page**

**STOMACH**

C16.0-C16.6, C16.8-C16.9

**3 Regional lymph node(s) involved only (continued)**

Right gastric (inferior gastric), NOS:

- Gastrocolic
- Gastroduodenal
- Gastroepiploic (gastro-omental), right or NOS
- Gastrohepatic
- Greater curvature
- Greater omental
- Infrapyloric
- Pancreaticoduodenal
- Pyloric, NOS:
  - Infrapyloric (subpyloric)
  - Suprapyloric

Splenic (lienal), NOS:

- Gastroepiploic (gastro-omental), left
- Splenic hilar

Nodule(s) in perigastric fat

Regional lymph node(s), NOS

**4 Regional by BOTH direct extension AND regional lymph node(s) involved**

Codes (2) + (3)

**5 Regional, NOS**

**7 Distant site(s)/lymph node(s) involved**

Distant lymph node(s):

- Inferior mesenteric
- Para-aortic
- Porta hepatis (portal) (hilar) [in hilus of liver]
- Retroperitoneal
- Superior mesenteric
- Other distant lymph node(s)

Extension to:

- Abdominal wall
- Adrenal (suprarenal) gland
- Kidney
- Retroperitoneum

Further contiguous extension

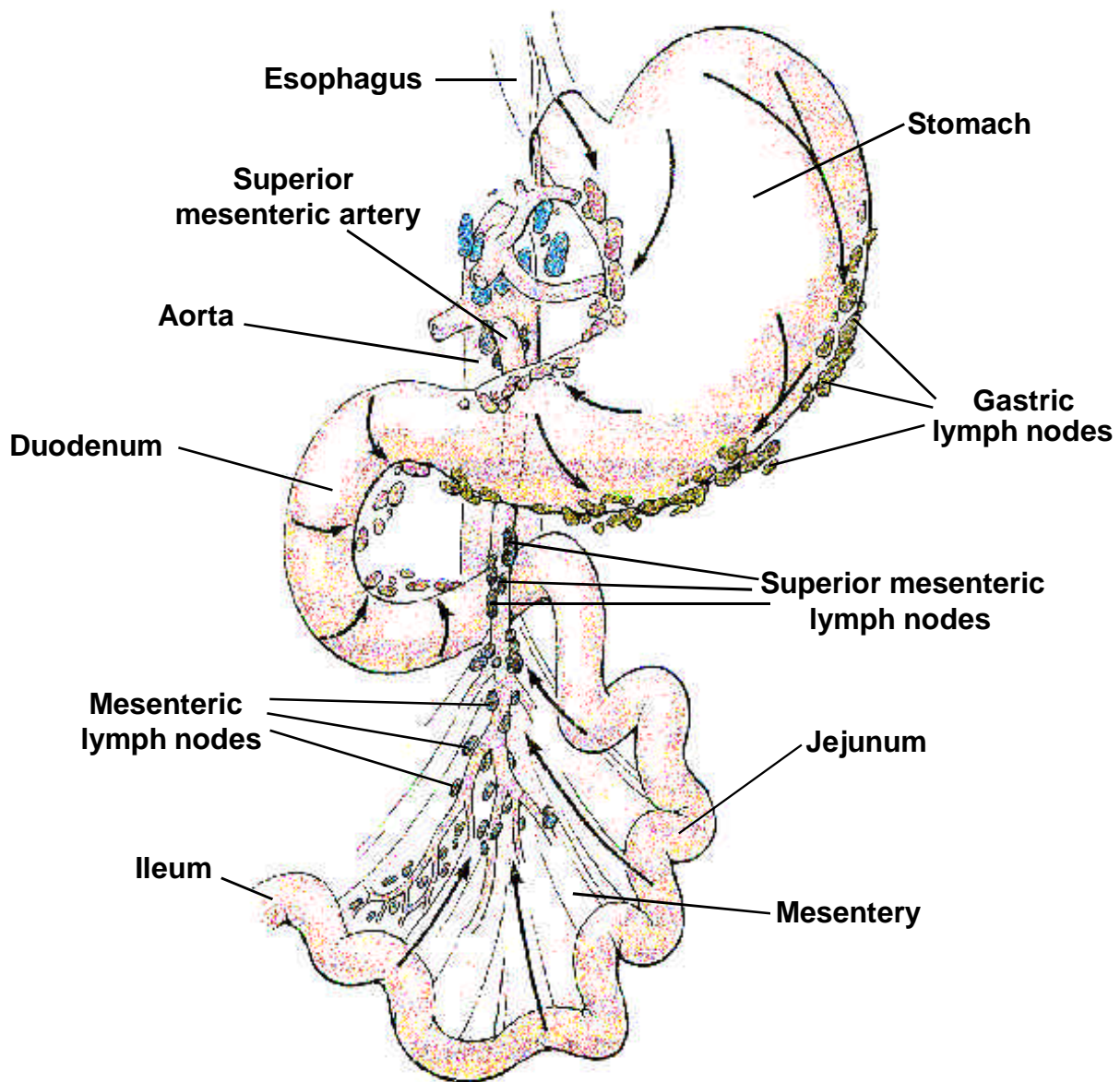
Metastasis

**9 Unknown if extension or metastasis**

- # Considered localized in Historic Stage
- ## Considered regional in Historic Stage
- ### Considered distant in Historic Stage
- \*\* Considered regional in 1977 Summary Staging Guide
- \*\*\* Considered distant in 1977 Summary Staging Guide



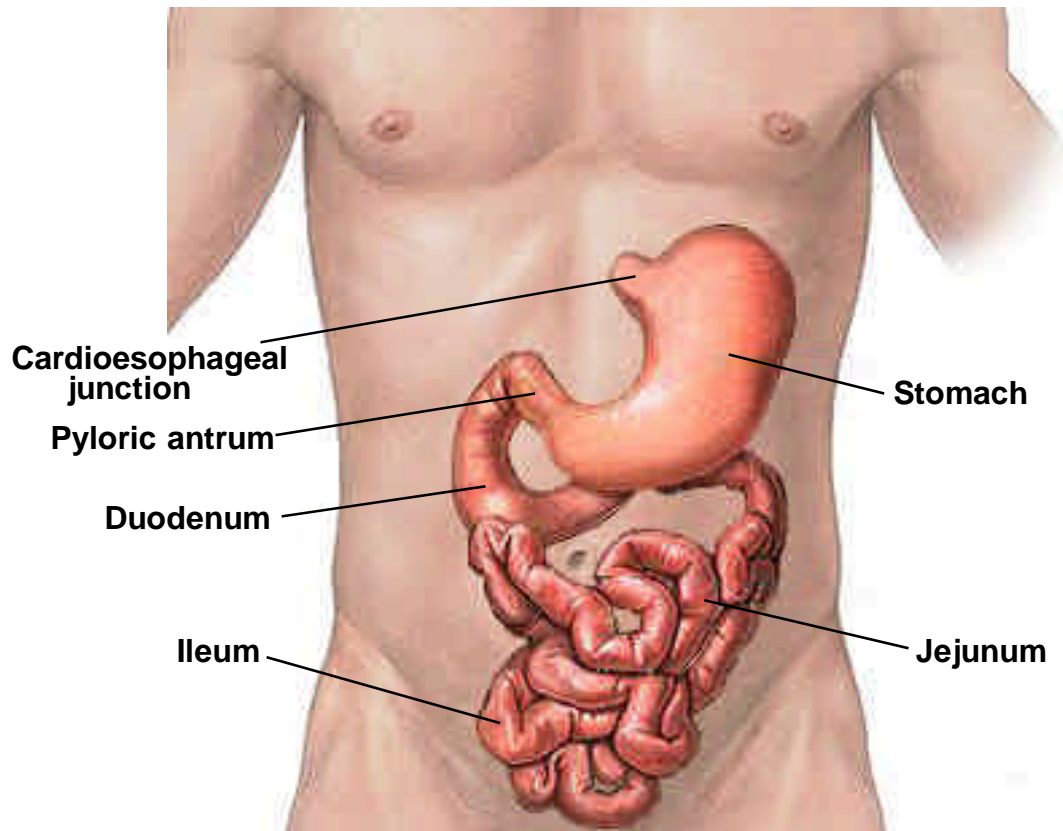
## ANATOMIC DRAWINGS OF THE SMALL INTESTINES



### STOMACH AND SMALL INTESTINE WITH LYMPH NODES

Arrows show the direction of lymph node drainage

## ANATOMIC DRAWINGS OF THE SMALL INTESTINES



## **SMALL INTESTINE**

C17.0-C17.3, C17.8-C17.9

C17.0 Duodenum

C17.1 Jejunum

C17.2 Ileum (excludes ileocecal valve, C18.0)

C17.3 Meckel diverticulum (site of neoplasm)

C17.8 Overlapping lesion of small intestine

C17.9 Small intestine, NOS

## **SUMMARY STAGE**

**0 In situ:** Noninvasive; intraepithelial  
(Adeno)carcinoma in a polyp, noninvasive

### **1 Localized only**

Invasive tumor confined to:

Intramucosa

Lamina propria

Mucosa, NOS

Muscularis mucosae

Muscularis, NOS

Muscularis propria

Polyp, NOS:

Head of polyp

Stalk of polyp

Submucosa (superficial invasion)

Subserosal tissue/(sub)serosal fat

Transmural, NOS

Wall, NOS

Extension through wall, NOS

Intraluminal to other segments of small intestine or cecum

Invasion through muscularis propria or muscularis, NOS

Localized, NOS

**2 Regional by direct extension only**

Extension to:

**All small intestine sites:**

Abdominal wall  
Adjacent tissue(s), NOS  
Connective tissue:  
    Mesenteric fat  
    Mesentery  
    Nonperitonealized perimuscular tissue  
    Retroperitoneum  
Fat, NOS

**Duodenum:**

Ampulla of Vater  
Blood vessel(s) (major):  
    Aorta  
    Gastroduodenal artery  
    Portal vein  
    Renal vein  
    Superior mesenteric artery or vein  
    Vena cava  
Diaphragm  
Extrahepatic bile duct(s)  
Gallbladder  
Hepatic flexure  
Kidney, NOS:  
    Kidney, right  
Liver, NOS:  
    Liver, quadrate lobe  
    Liver, right lobe  
Omentum, NOS:  
    Greater omentum  
Pancreas  
Pancreatic duct  
Stomach<sup>###</sup>  
Transverse colon  
Ureter, right

**Jejunum and Ileum:**

Colon including appendix

Other segments of small intestine via serosa

**Code 2 continued on next page**

**SMALL INTESTINE**  
C17.0-C17.3, C17.8-C17.9

**2 Regional by direct extension only (continued)**

Invasion of/through:

**All sites:**

Mesothelium<sup>#\*</sup>

Serosa<sup>#\*</sup>

Tunica serosa<sup>#\*</sup>

Visceral peritoneum<sup>#\*</sup>

**3 Regional lymph node(s) involved only**

REGIONAL Lymph Nodes

Pericholedochal (common bile duct)<sup>#####</sup>

**Duodenum:**

Duodenal

Gastroduodenal<sup>###</sup>

Hepatic<sup>###</sup>

Infrapyloric (subpyloric)<sup>###</sup>

Pancreaticoduodenal

Pyloric<sup>###</sup>

Superior mesenteric<sup>#####</sup>

**Jejunum and Ileum:**

Ileocolic **for terminal ileum only**

Mesenteric, NOS

Posterior cecal (retrocecal) **for terminal ileum only**

Superior mesenteric<sup>#####</sup>

Regional lymph node(s), NOS

**4 Regional by BOTH direct extension AND regional lymph node(s) involved**

Codes (2) + (3)

**5 Regional, NOS**

**7 Distant site(s)/node(s) involved**

Distant lymph node(s)

**Jejunum and Ileum:**

Bladder<sup>##</sup>

Fallopian tube(s)<sup>##</sup>

Ovary(ies)<sup>##</sup>

Uterus<sup>##</sup>

Further contiguous extension

Metastasis

**9 Unknown if extension or metastasis**

# Considered localized in Historic Stage

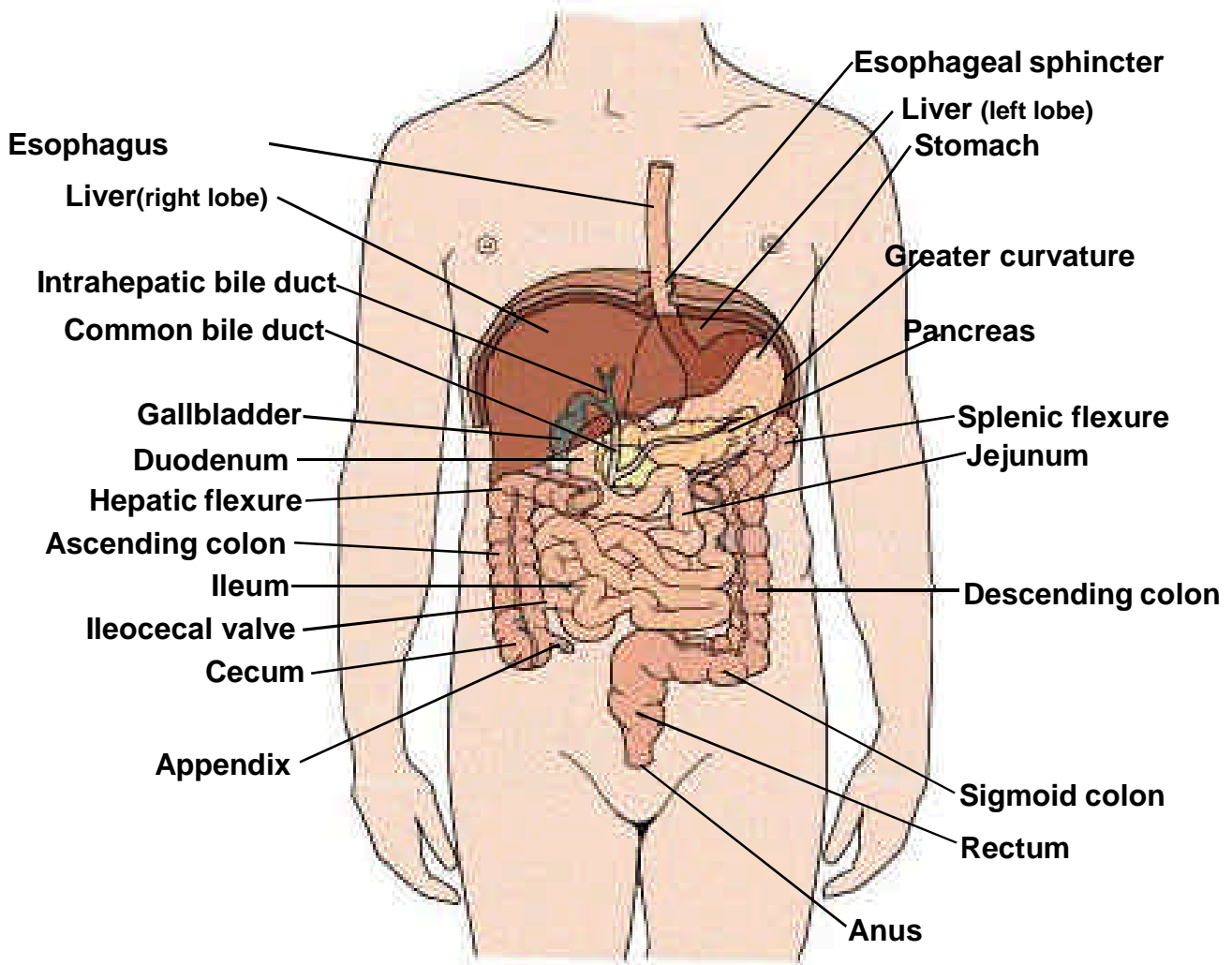
## Considered regional in Historic Stage

### Considered distant in Historic Stage

\* Considered localized in 1977 Summary Staging Guide

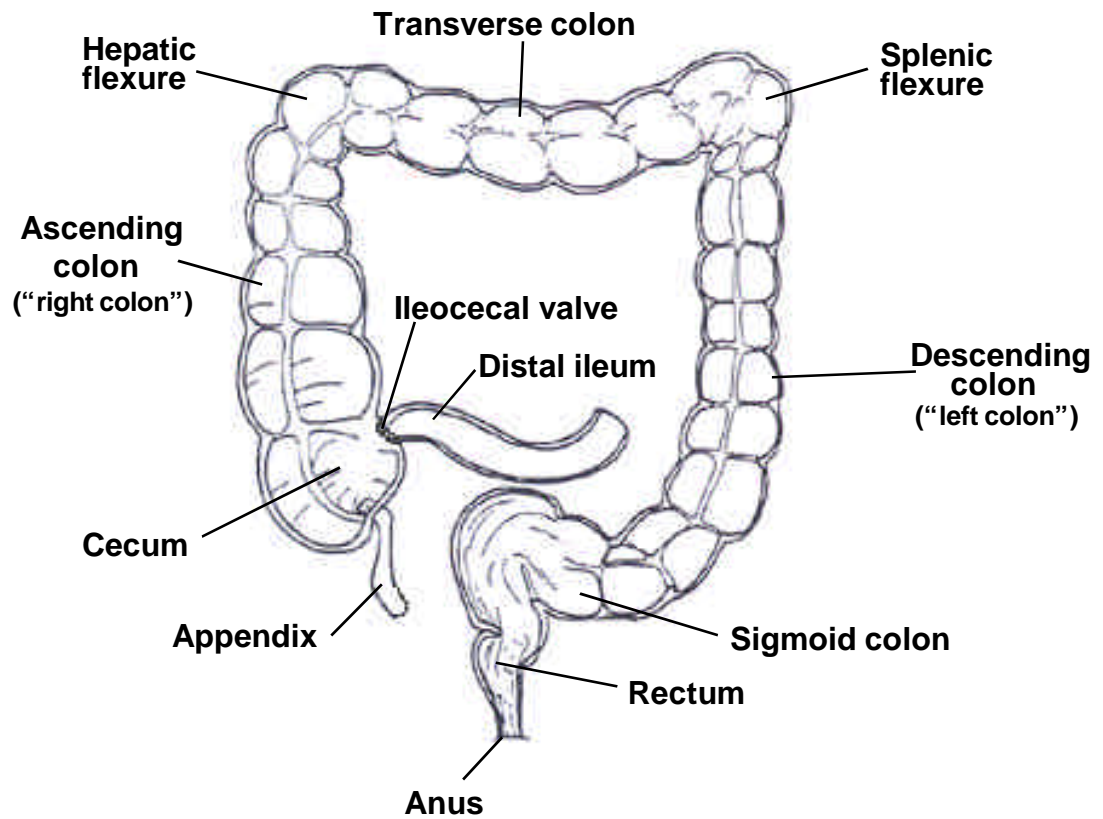
\*\*\* Considered distant in 1977 Summary Staging Guide

## ANATOMIC DRAWINGS OF THE COLON




## THE ALIMENTARY CANAL

## ANATOMIC DRAWINGS OF THE COLON



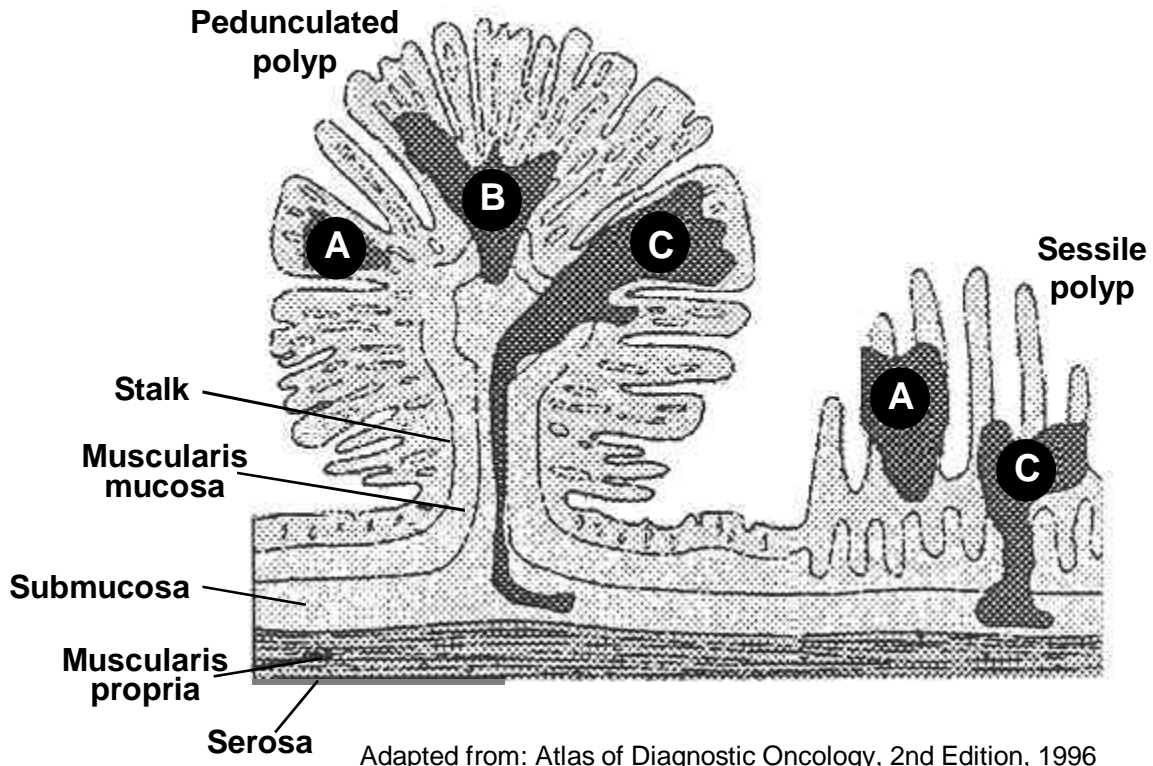
COLON, RECTUM, AND ANUS



LAYERS OF THE COLON WALL OF COLON



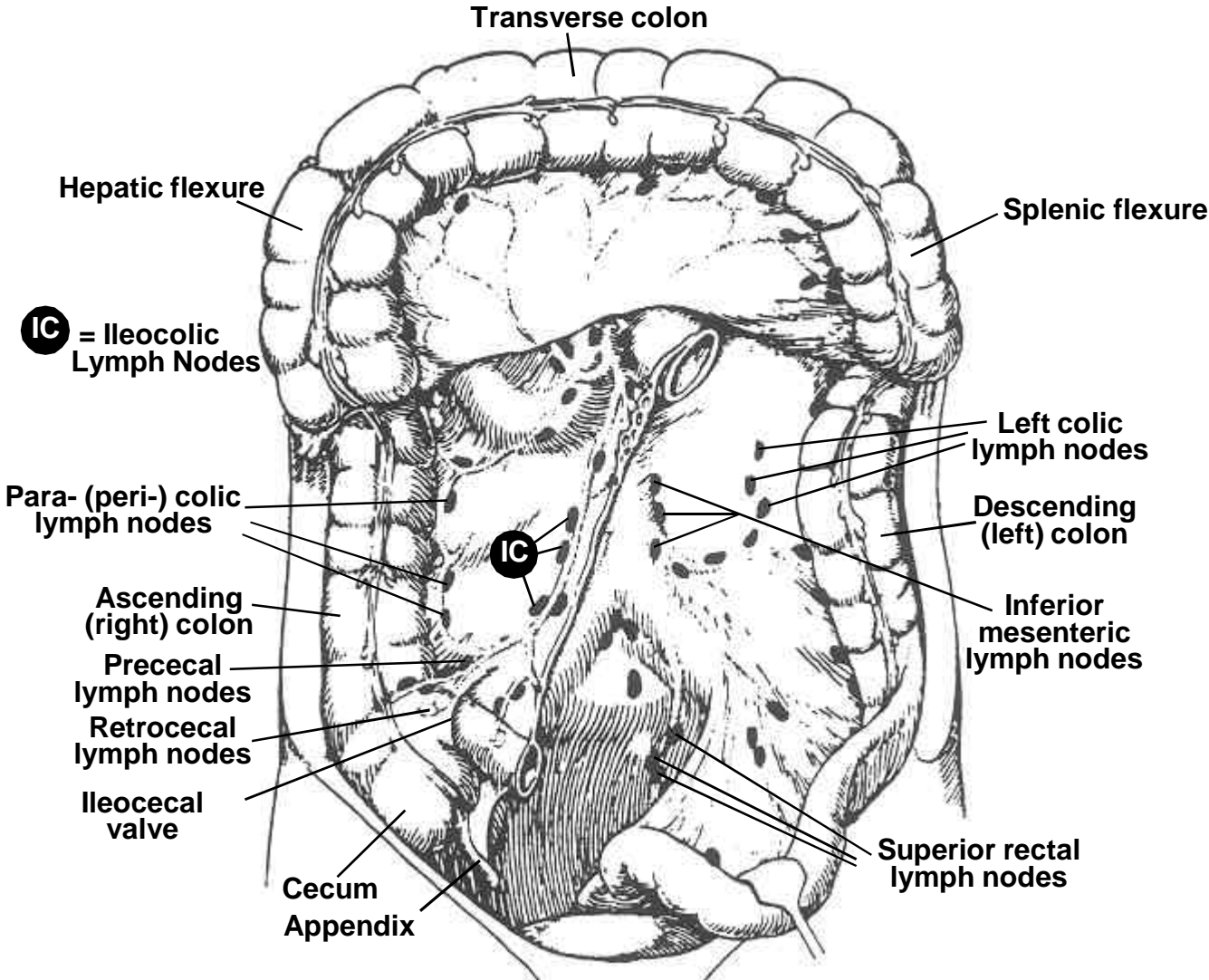
## ANATOMIC DRAWINGS OF THE COLON



The dark areas (with labels A, B, and C) represent zones of carcinoma. Area A in both the pedunculated polyp and the sessile (or flat) polyp shows no invasion and is therefore in situ. Areas B and C in both polyps are invasive. Notice that polyps are “bulges” in the colon wall with the corresponding layers of the colon wall (see layers of the colon wall on page 85) within them.

### CARCINOMA IN A POLYP

**ANATOMIC DRAWINGS OF THE COLON**



**COLON AND LYMPH NODES**

## **COLON**

C18.0-C18.9

C18.0 Cecum

C18.1 Appendix

C18.2 Ascending (right) colon

C18.3 Hepatic flexure of colon

C18.4 Transverse colon

C18.5 Splenic flexure of colon

C18.6 Descending (left) colon

C18.7 Sigmoid colon

C18.8 Overlapping lesion of colon

C18.9 Colon, NOS

## **SUMMARY STAGE**

**0 In situ:** Noninvasive; intraepithelial  
(Adeno)carcinoma in a polyp or adenoma, noninvasive

### **1 Localized only**

Invasive tumor confined to:

Intramucosa, NOS

Lamina propria

Mucosa, NOS

Muscularis mucosae

Muscularis propria

Perimuscular tissue invaded

Polyp, NOS:

Head of polyp

Stalk of polyp

Submucosa (superficial invasion)

Subserosal tissue/(sub)serosal fat

Transmural, NOS

Wall, NOS

Confined to colon, NOS

Extension through wall, NOS

Invasion through muscularis propria or muscularis, NOS

Localized, NOS

**Note:** Ignore intraluminal extension to adjacent segment(s) of colon/rectum or to the ileum from the cecum.

**2 Regional by direct extension only**

Extension to:

**All colon sites:**

Invasion of/through serosa (mesothelium) (visceral peritoneum)<sup>#</sup>

Extension into/through:

Abdominal wall<sup>###</sup>  
Adjacent tissue(s), NOS  
Connective tissue  
Fat, NOS  
Greater omentum  
Mesenteric fat  
Mesentery  
Mesocolon  
Pericolonic fat  
Retroperitoneum (excluding fat)<sup>###</sup>  
Small intestine

**Ascending colon:**

Kidney, right<sup>###</sup>  
Liver, right lobe  
Retroperitoneal fat<sup>###</sup>  
Ureter, right<sup>###</sup>

**Transverse colon and flexures:**

Bile ducts<sup>###</sup>  
Gallbladder<sup>###</sup>  
Gastrocolic ligament  
Kidney  
Liver  
Pancreas  
Spleen  
Stomach<sup>###</sup>

**Descending colon:**

Kidney, left<sup>###</sup>  
Pelvic wall<sup>###</sup>  
Retroperitoneal fat<sup>###</sup>  
Spleen  
Ureter, left

**Sigmoid colon:**

Pelvic wall<sup>###</sup>

**COLON**  
C18.0-C18.9

**3 Regional lymph node(s) involved only**

REGIONAL Lymph Nodes

**All colon subsites:**

Colic, NOS  
Epicolic (adjacent to bowel wall)  
Mesenteric, NOS  
Paracolic/pericolic

Nodule(s) in pericolic fat

**Cecum and Appendix:**

Cecal, NOS  
    Anterior (prececal)  
    Posterior (retrocecal)  
Ileocolic  
Right colic

**Ascending colon:**

Ileocolic  
Middle colic  
Right colic

**Transverse colon and flexures:**

Inferior mesenteric **for splenic flexure only**  
Left colic **for splenic flexure only**  
Middle colic<sup>‡</sup>  
Right colic **for hepatic flexure only**

**Descending colon:**

Inferior mesenteric  
Left colic  
Sigmoid<sup>###</sup>

**Sigmoid:**

Inferior mesenteric  
Sigmoidal (sigmoid mesenteric)  
Superior hemorrhoidal<sup>###</sup>  
Superior rectal<sup>###</sup>

Regional lymph node(s), NOS

**4 Regional by BOTH direct extension AND regional lymph node(s) involved**

Codes (2) + (3)

**5 Regional, NOS**

**7 Distant site(s)/node(s) involved**

**All colon sites** unless included in code 2

Distant lymph node(s):

- Para-aortic
- Retroperitoneal
- Superior mesenteric<sup>§</sup>
- Other distant lymph node(s)

Extension to:

- Adrenal (suprarenal) gland
- Bladder
- Diaphragm
- Fallopian tube<sup>£</sup>
- Fistula to skin
- Gallbladder
- Other segment(s) of colon via serosa
- Ovary<sup>£</sup>
- Uterus<sup>£</sup>

**Cecum and appendix:**

Distant lymph node(s):

- Inferior mesenteric
- Other distant lymph node(s)

Extension to:

- Kidney, right
- Liver<sup>##</sup>
- Ureter, right

**Ascending colon:**

Distant lymph node(s):

- Inferior mesenteric
- Other distant lymph node(s)

**Transverse colon and flexures:**

Distant lymph node(s):

- Inferior mesenteric **for hepatic flexure and transverse colon only**
- Other distant lymph node(s)

Extension to:

- Ureter

**Sigmoid colon:**

Extension to:

- Cul de sac (rectouterine pouch)
- Ureter

Further contiguous extension

Metastasis

## **9 Unknown if extension or metastasis**

£ Considered regional for cecum, ascending, descending and sigmoid for Historic stage

§ Considered regional for cecum, appendix, ascending, hepatic flexure and transverse colon in 1977  
Summary Staging Guide

¥ Considered distant for splenic flexure in Historic stage

**Note 1:** Ignore intraluminal extension to adjacent segment(s) of colon/rectum and code depth of invasion or extracolonic spread as indicated.

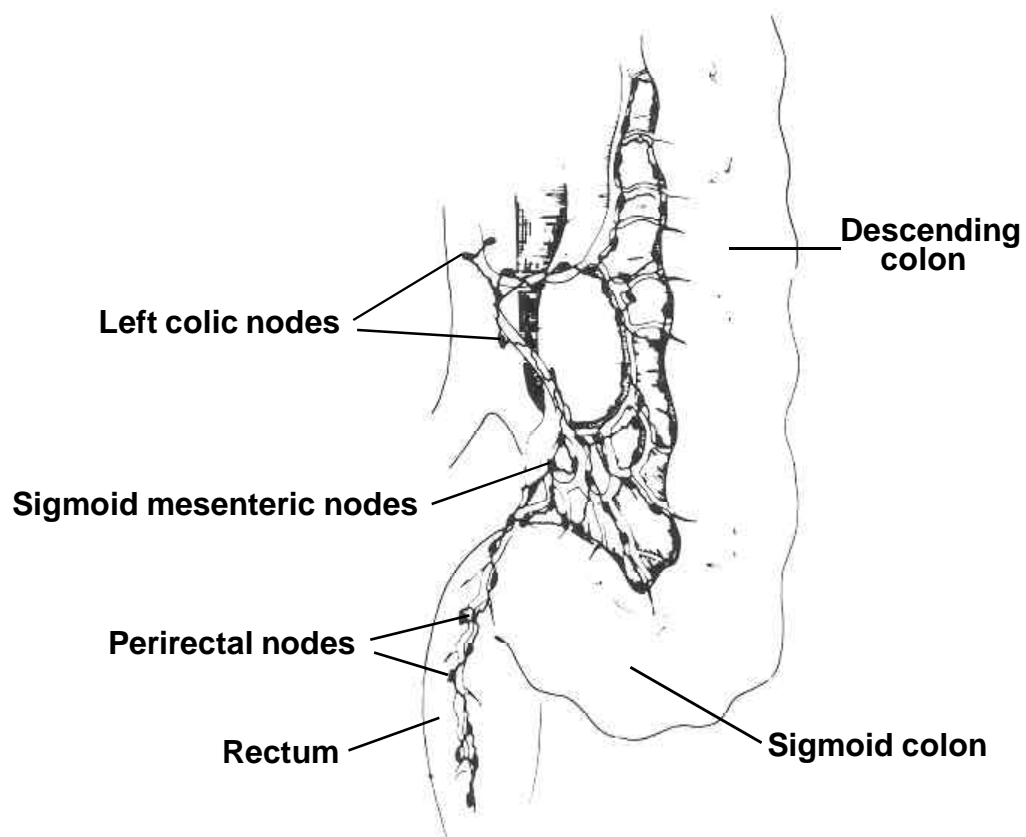
**Note 2:** Terminology such as “Transmural, NOS” and “Extension through the wall, NOS” typically means that the tumor has invaded the muscularis propria but has not necessarily invaded the entire thickness of the colon wall.

# Considered localized in Historic Stage

## Considered regional in Historic Stage

### Considered distant in Historic Stage

## ANATOMIC DRAWING OF THE COLON AND RECTUM



### LOWER COLON AND RECTUM AND PRINCIPAL LYMPH NODES



## **RECTOSIGMOID JUNCTION, RECTUM**

C19.9, C20.9

C19.9 Rectosigmoid junction

C20.9 Rectum, NOS

### **SUMMARY STAGE**

**0 In situ:** Noninvasive; intraepithelial  
(Adeno)carcinoma in a polyp, noninvasive

### **1 Localized only**

Invasive tumor confined to:

Intramucosa, NOS

Lamina propria

Mucosa, NOS

Muscularis mucosae

Muscularis propria

Perimuscular tissue invaded

Polyp, NOS:

Head of polyp

Stalk of polyp

Submucosa (superficial invasion)

Subserosal tissue/(sub)serosa fat invaded

Transmural, NOS

Extension through wall, NOS

Invasion through muscularis propria or muscularis, NOS

Localized, NOS

### **2 Regional by direct extension only**

Invasion of/through serosa (mesothelium) (visceral peritoneum)<sup>#</sup>

Extension to/through:

Adjacent tissue(s), NOS

Connective tissue

Fat, NOS

Perirectal fat

#### **Rectosigmoid:**

Cul de sac (rectouterine pouch)

Mesenteric fat

Mesentery

Mesocolon

Pelvic wall

Pericolonic fat

Small intestine

**Code 2 continued on next page**

**2 Regional by direct extension only (continued)**

**Rectum:**

Anus  
Bladder **for males only**  
Cul de sac (rectouterine pouch)  
Ductus deferens  
Pelvic wall  
Prostate  
Rectovaginal septum  
Rectovesical fascia **for males only**  
Seminal vesicle(s)  
Skeletal muscle of pelvic floor  
Vagina

**3 Regional lymph node(s) involved only**

REGIONAL Lymph Nodes

**Rectosigmoid:**

Colic, NOS:###  
    Left colic###  
Hemorrhoidal, superior or middle  
Inferior mesenteric  
Mesenteric, NOS  
Paracolic/pericolic  
Perirectal  
Rectal  
Sigmoidal (sigmoid mesenteric)  
Superior rectal

Nodule(s) in pericolic fat

**Rectum:**

Hemorrhoidal, superior, middle or inferior  
Inferior mesenteric  
Internal iliac (hypogastric), NOS:###  
    Obturator  
Mesenteric, NOS  
Perirectal  
Rectal  
Sacral, NOS:###  
    Lateral (laterosacral)  
    Middle sacral (promontorial) (Gerota's node)  
    Presacral  
Sigmoidal (sigmoid mesenteric)

Nodule(s) in perirectal fat

Regional lymph node(s), NOS

## RECTOSIGMOID JUNCTION, RECTUM

C19.9, C20.9

### 4 Regional by BOTH direct extension AND regional lymph node(s) involved

Codes (2) + (3)

### 5 Regional, NOS

### 7 Distant site(s)/node(s) involved

Distant lymph node(s):

Internal iliac (hypogastric), NOS: **for rectosigmoid:** \*\*

Obturator **for rectosigmoid**

Left colic **for rectum**##

Other distant lymph node(s)

Extension to:

#### **Rectosigmoid:**

Bladder##

Colon via serosa##

Fallopian tube(s)##

Ovary(ies)##

Prostate##

Ureter(s)

Uterus##

#### **Rectum:**

Bladder **for females only**##

Bone(s) of pelvis##

Urethra##

Uterus###

Further contiguous extension

Metastasis

### 9 Unknown if extension or metastasis

**Note 1:** Ignore intraluminal extension to adjacent segment(s) of colon/rectum and code depth of invasion or extracolonic spread as indicated.

**Note 2:** Terminology such as “Transmural, NOS”, and “Extension through the wall, NOS” typically means that the tumor has invaded the muscularis propria but has not necessarily invaded the entire thickness of the colon wall. (See drawing.)

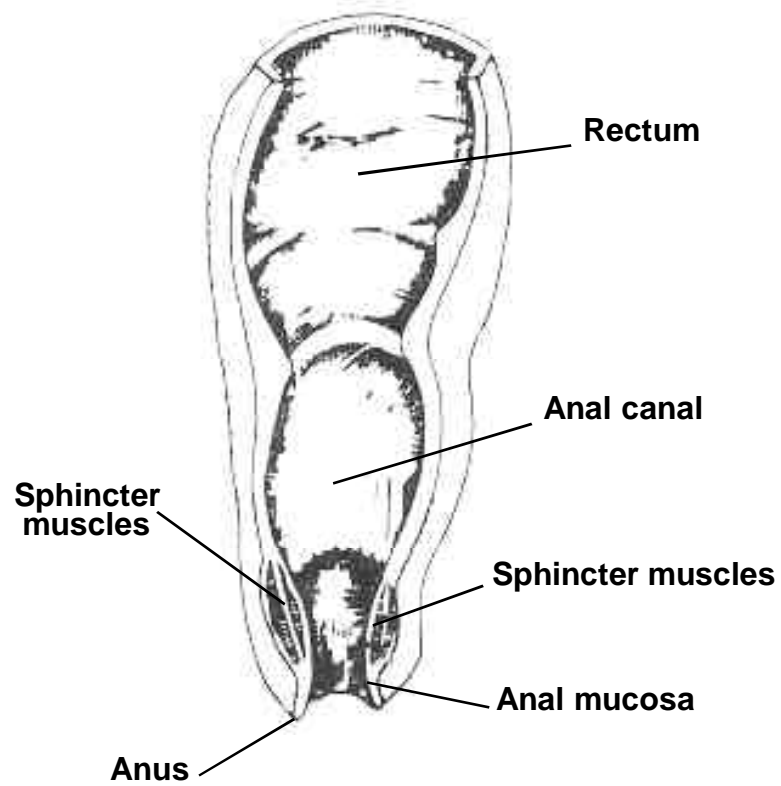
# Considered localized in Historic Stage

## Considered regional in Historic Stage

### Considered distant in Historic Stage

\*\* Considered regional in 1977 Summary Staging Guide

## ANATOMIC DRAWING OF THE ANUS AND ANAL CANAL



ANUS AND ANAL CANAL

## ANUS AND ANAL CANAL

C21.0-C21.2, C21.8

C21.0 Anus, NOS

C21.1 Anal canal

C21.2 Cloacogenic zone

C21.8 Overlapping lesion of rectum, anus and anal canal

### SUMMARY STAGE

**0 In situ:** Noninvasive; intraepithelial

#### 1 Localized only

Incidental finding of malignancy in hemorrhoid

Invasive tumor confined to:

Intramucosa

Lamina propria

Mucosa, NOS

Muscularis mucosae

Muscularis propria (internal sphincter)

Submucosa (superficial invasion)

Localized, NOS

#### 2 Regional by direct extension only

Extension to:

Ischiorectal fat/tissue

Perianal skin

Perineum

Rectal mucosa or submucosa

Skeletal muscles:

Anal sphincter (external)

Levator ani

Subcutaneous perianal tissue

Vulva

#### 3 Regional lymph node(s) involved only

REGIONAL Lymph Nodes

Anorectal

Inferior hemorrhoidal

Internal iliac (hypogastric), NOS: **for anus<sup>#####</sup> and anal canal:<sup>###</sup>**

Obturator **for anus<sup>#####</sup> and anal canal<sup>###</sup>**

Lateral sacral (laterosacral)<sup>###</sup>

Perirectal

Superficial inguinal (femoral) **for anus and anal canal<sup>\*\*\*</sup>**

Regional lymph node(s), NOS

**4 Regional by BOTH direct extension AND regional lymph node(s) involved**

Codes (2) + (3)

**5 Regional, NOS**

**7 Distant site(s)/node(s) involved**

Distant lymph node(s)

Extension to:

Bladder<sup>##</sup>

Broad ligament(s)<sup>##</sup>

Cervix uteri<sup>##</sup>

Corpus uteri<sup>##</sup>

Pelvic peritoneum

Prostate<sup>##</sup>

Urethra<sup>##</sup>

Vagina<sup>##</sup>

Further contiguous extension

Metastasis

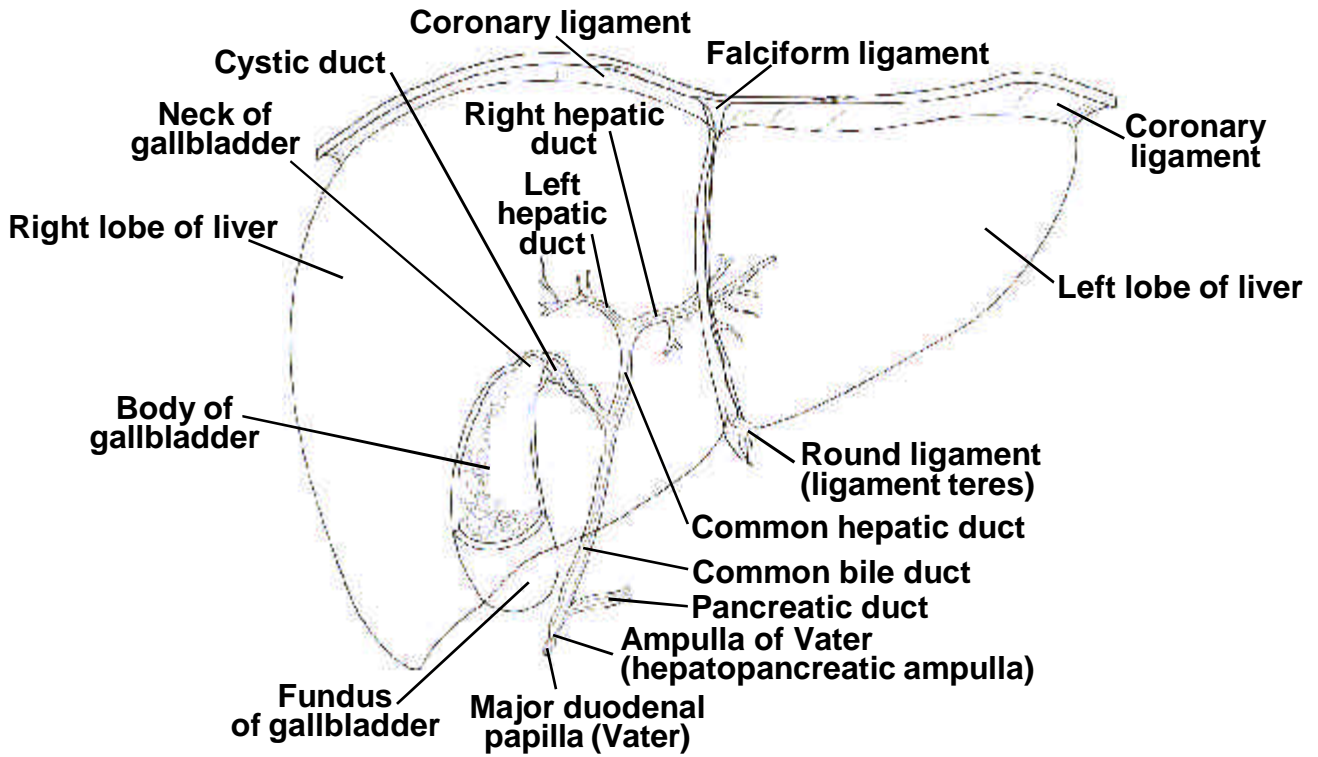
**9 Unknown if extension or metastasis**

<sup>##</sup> Considered regional in Historic Stage

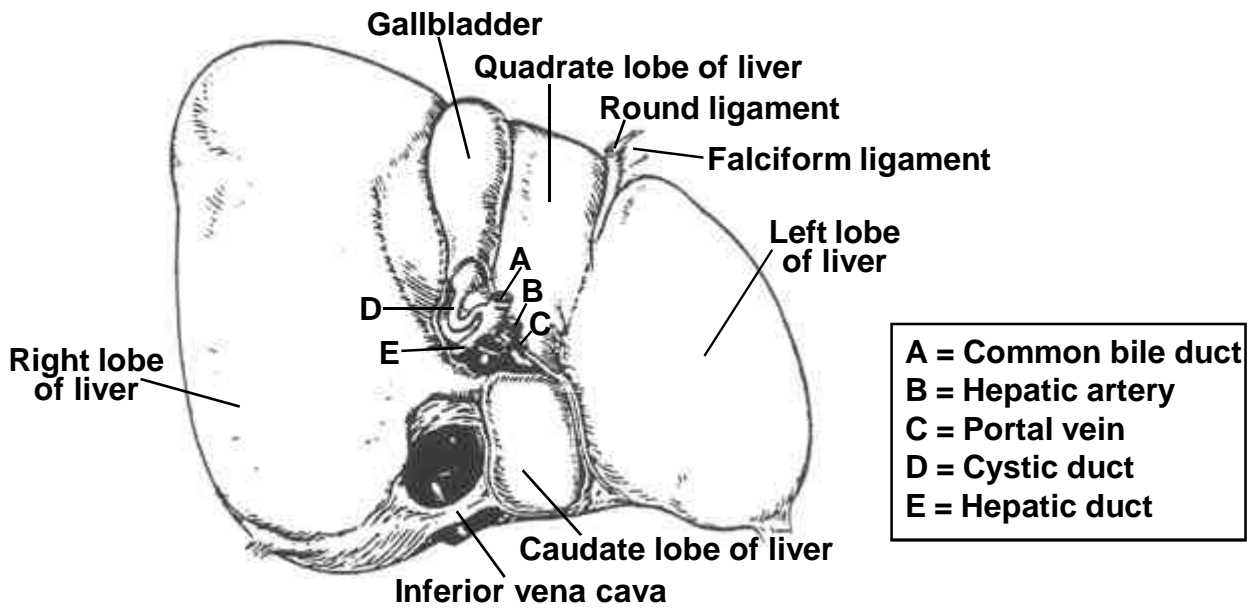
<sup>###</sup> Considered distant in Historic Stage

<sup>\*\*\*</sup> Considered distant in 1977 Summary Staging Guide

## ANATOMIC DRAWINGS OF THE BILIARY TRACT

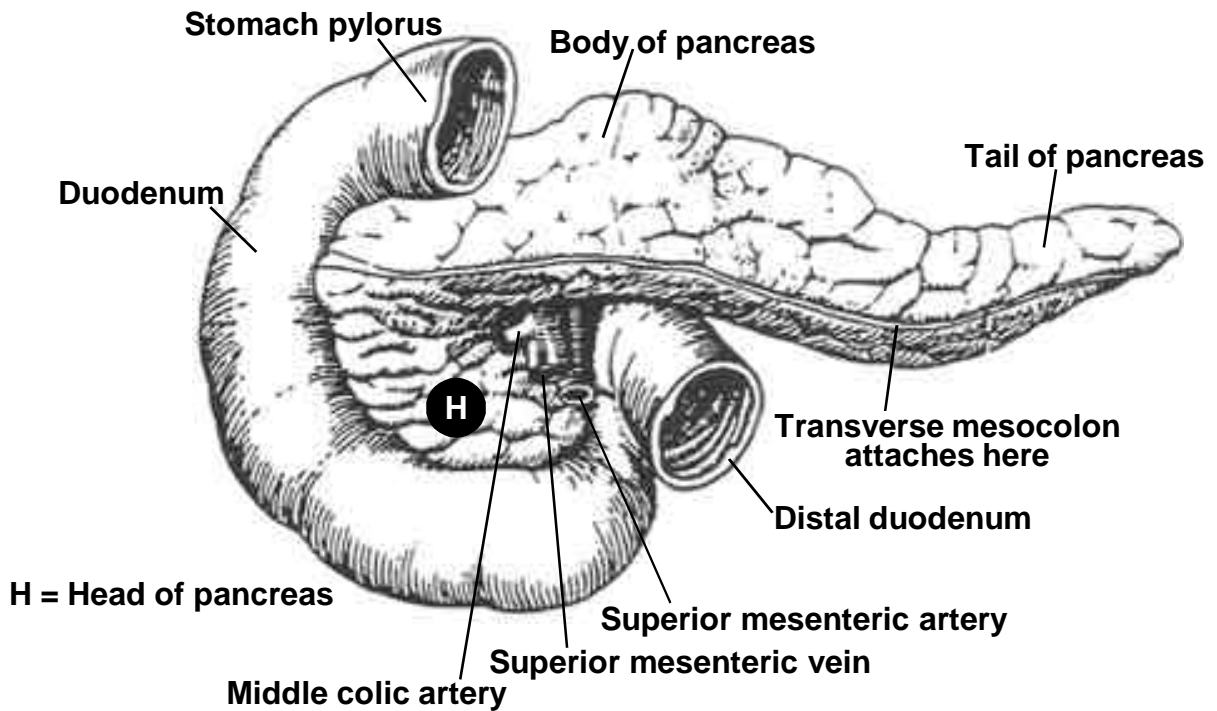


**ANTERIOR VIEW OF THE LIVER**

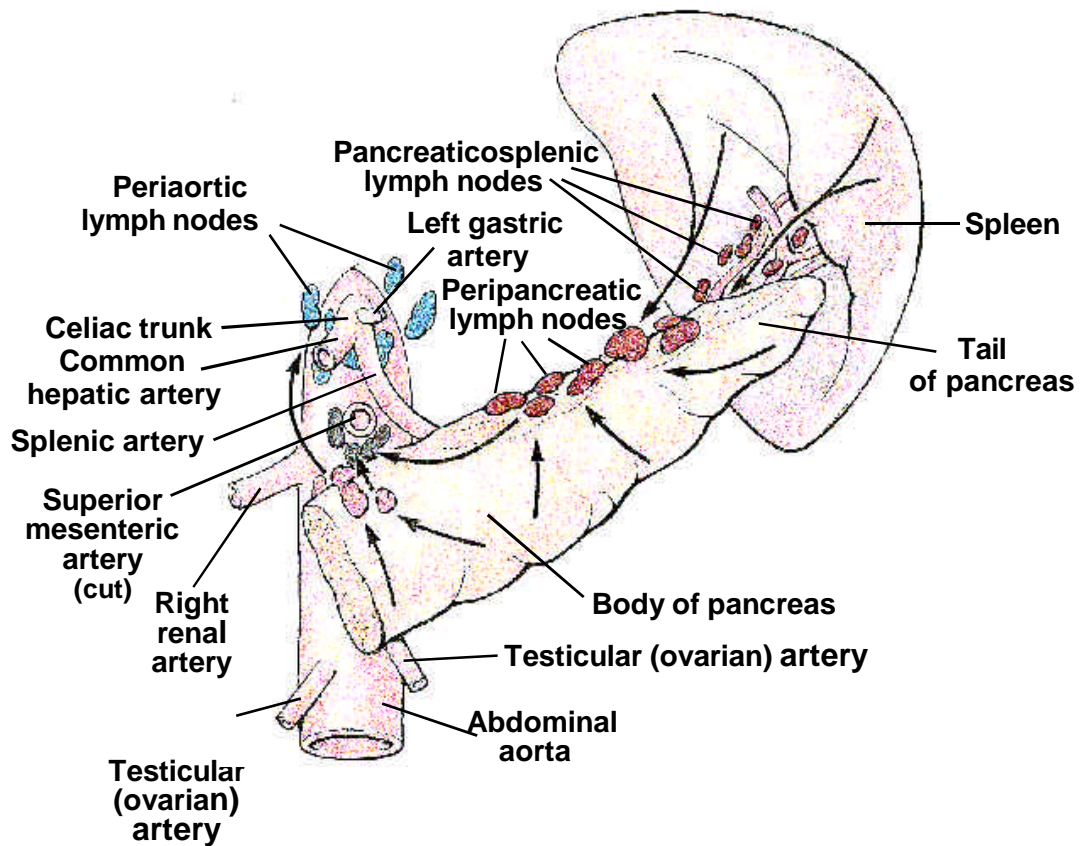


**UNDERSURFACE OF THE LIVER**

## ANATOMIC DRAWINGS OF THE BILIARY TRACT



## THE PANCREAS



**BODY AND TAIL OF PANCREAS**  
(arrows show direction of lymphatic drainage)



## LIVER AND INTRAHEPATIC BILE DUCTS

C22.0-C22.1

C22.0 Liver

C22.1 Intrahepatic bile duct

### SUMMARY STAGE

**0 In situ:** Noninvasive; intraepithelial

#### 1 Localized

Confined to one lobe with or without vascular invasion

Multiple (satellite) nodules/tumors confined to one lobe

Confined to liver, NOS

Localized, NOS

#### 2 Regional by direct extension only

More than one lobe involved by contiguous growth (single lesion)

Extension to:

Diaphragm

Extrahepatic bile duct(s)

Extrahepatic blood vessel(s):

Hepatic artery

Portal vein

Vena cava

Gallbladder

Lesser omentum<sup>###</sup>

Ligament(s):<sup>###</sup>

Coronary

Falciform

Round [of liver]

Hepatoduodenal

Hepatogastric

Triangular

Peritoneum, NOS:<sup>###</sup>

Parietal<sup>###</sup>

Visceral<sup>###</sup>

Multiple (satellite) nodules/tumors in more than one lobe of liver or on surface of  
parenchyma<sup>\*\*\*</sup>

Satellite nodules, NOS<sup>\*\*\*</sup>

**3 Regional lymph node(s) involved only**

REGIONAL Lymph Nodes

Hepatic, NOS:

Hepatic artery

Hepatic pedicle

Inferior vena cava

Porta hepatis (portal) (hilar) [in hilus of liver]

Periportal<sup>###</sup>

Regional lymph node(s), NOS

**4 Regional by BOTH direct extension AND regional lymph node(s) involved**

Codes (2) + (3)

**5 Regional, NOS**

**7 Distant site(s)/lymph node(s) involved**

Distant lymph nodes:

Aortic, NOS:

Lateral (lumbar)

Para-aortic

Periaortic

Cardiac<sup>##\*\*</sup>

Coronary artery<sup>##\*\*</sup>

Diaphragmatic:

Pericardial (pericardiac)<sup>##\*\*</sup>

Peripancreatic

Posterior mediastinal (tracheoesophageal) including juxtaphrenic nodes<sup>##\*\*</sup>

Renal artery<sup>##\*\*</sup>

Retroperitoneal, NOS<sup>\*\*</sup>

Other distant lymph node(s)

Extension to:

Pancreas

Pleura<sup>##</sup>

Stomach

Further contiguous extension

Metastasis

**9 Unknown if extension or metastasis**

## Considered regional in Historic Stage

### Considered distant in Historic Stage

\*\* Considered regional in 1977 Summary Staging Guide

\*\*\* Considered distant in 1977 Summary Staging Guide

## **GALLBLADDER, OTHER BILIARY, AND BILIARY, NOS**

C23.9, C24.8-C24.9

C23.9 Gallbladder

C24.8 Overlapping lesion of biliary tract

C24.9 Biliary tract, NOS

### **SUMMARY STAGE**

**0 In situ:** Noninvasive; intraepithelial

#### **1 Localized only**

Invasive tumor confined to:

Lamina propria

Mucosa, NOS

Muscularis propria

Submucosa (superficial invasion)

Localized, NOS

#### **2 Regional by direct extension only**

Extension (in)to one of the following:

Ampulla of Vater

Duodenum

Extrahepatic bile duct(s)

Liver, NOS:

≤2 cm into liver

Omentum, NOS:

Greater

Lesser<sup>###</sup>

Pancreas

Perimuscular connective tissue

Small intestine, NOS

Invasion of/through serosa<sup>#\*</sup>

**GALLBLADDER, OTHER BILIARY, AND BILIARY, NOS**  
C23.9, C24.8-C24.9

**3 Regional lymph node(s) involved only**

REGIONAL Lymph Nodes

Celiac  
Cystic duct (Calot's node)  
Node of the foramen of Winslow (epiploic) (omental)###  
Pancreaticoduodenal  
Pericholedochal (common bile duct)####\*\*  
Periduodenal####\*\*  
Peripancreatic (near head of pancreas only)\*\*  
Periportal  
Porta hepatis (portal) (hilar) [in hilus of liver]####\*\*  
Superior mesenteric

Regional lymph node(s), NOS

**4 Regional by BOTH direct extension AND regional lymph node(s) involved**

Codes (2) + (3)

**5 Regional, NOS**

**7 Distant site(s)/node(s) involved**

Distant lymph node(s):

Para-aortic  
Other distant lymph node(s)

Extension to one of the following:

Blood vessel(s) (major):\*\*  
Cystic artery/vein  
Hepatic artery  
Portal vein  
Colon##  
Liver > 2 cm##  
Stomach##

Extension to two or more adjacent organs##

Further contiguous extension

Metastasis

**9 Unknown if extension or metastasis**

# Considered localized in Historic Stage  
## Considered regional in Historic Stage  
### Considered distant in Historic Stage  
\* Considered localized in 1977 Summary Staging Guide  
\*\* Considered regional in 1977 Summary Staging Guide  
\*\*\* Considered distant in 1977 Summary Staging Guide

## **EXTRAHEPATIC BILE DUCT**

C24.0

C24.0 Extrahepatic bile duct

(choledochal, common, cystic, and hepatic bile duct; sphincter of Oddi)

**Note:** Sites C24.8-C24.9 (Biliary tract, NOS) are included with gallbladder, C23.9.

### **SUMMARY STAGE**

**0 In situ:** Noninvasive, intraepithelial

#### **1 Localized only**

Invasive tumor of extrahepatic bile duct(s) (choledochal, common cystic, and hepatic) confined to:

Lamina propria

Mucosa, NOS

Muscularis propria

Submucosa

Localized, NOS

#### **2 Regional by direct extension only**

Extension to:

Blood vessel(s) (major):

Hepatic artery

Portal vein

Colon, NOS:

Transverse including flexures

Other parts of colon<sup>\*\*\*</sup>

Duodenum

Gallbladder

Liver including porta hepatis

Omentum, NOS:

Greater<sup>\*\*\*</sup>

Lesser

Pancreas

Periductal/fibromuscular connective tissue

Stomach, NOS:

Distal

Proximal<sup>\*\*\*</sup>

**3 Regional lymph node(s) involved only**

REGIONAL Lymph Nodes

Cystic duct (Calot's node)  
Node of the foramen of Winslow (epiploic) (omental)  
Pancreaticoduodenal  
Pericholedochal (common bile duct)  
Periduodenal  
Peripancreatic (near head of pancreas only)  
Periportal  
Porta hepatis (portal) (hilar) [in hilus of liver]

Regional lymph node(s), NOS

**4 Regional by BOTH direct extension AND regional lymph node(s) involved**

Codes (2) + (3)

**5 Regional, NOS**

**7 Distant site(s)/node(s) involved**

Distant lymph node(s):  
Celiac  
Para-aortic  
Superior mesenteric  
Other distant lymph node(s)

Further contiguous extension

Metastasis

**9 Unknown if extension or metastasis**

\*\*\* Considered distant in 1977 Summary Staging Guide

## **AMPULLA OF VATER**

C24.1

C24.1 Ampulla of Vater

### **SUMMARY STAGE**

**0 In situ:** Noninvasive; intraepithelial

#### **1 Localized only**

Invasive tumor confined to ampulla of Vater or extending to sphincter of Oddi

Localized, NOS

#### **2 Regional by direct extension only**

Extension to:

Blood vessel(s) (major):

Hepatic artery

Portal vein

Duodenum

Extrahepatic bile ducts excluding sphincter of Oddi

Gallbladder

Hepatic flexure

Lesser omentum

Liver including porta hepatis

Pancreas

Stomach, NOS:

Distal

Proximal\*\*\*

Transverse colon

**3 Regional lymph node(s) involved only**

REGIONAL Lymph Nodes

Celiac####  
Hepatic  
Infrapyloric (subpyloric)####  
Lateral aortic (lumbar)####  
Node of the foramen of Winslow (epiploic) (omental)  
Pancreaticoduodenal  
Peripancreatic  
Periportal  
Proximal mesenteric####  
Retroperitoneal####  
Superior mesenteric####

Lymph Nodes:

Anterior to ampulla of Vater  
Inferior to ampulla of Vater  
Posterior to ampulla of Vater  
Superior to ampulla of Vater

Regional lymph node(s), NOS

**4 Regional by BOTH direct extension AND regional lymph node(s) involved**

Codes (2) + (3)

**5 Regional, NOS**

**7 Distant site(s)/node(s) involved**

Distant lymph node(s):  
Para-aortic  
Other distant lymph node(s)

Further contiguous extension:  
Other adjacent organs

Metastasis

**9 Unknown if extension or metastasis**

### Considered distant in Historic Stage

\*\*\* Considered distant in 1977 Summary Staging Guide



## **PANCREAS: HEAD, BODY, AND TAIL**

C25.0-C25.4

C25.0 Head of pancreas

C25.1 Body of pancreas

C25.2 Tail of pancreas

C25.3 Pancreatic duct

C25.4 Islets of Langerhans

### **SUMMARY STAGE**

**0 In situ:** Noninvasive, intraepithelial

#### **1 Localized only**

Confined to pancreas

Localized, NOS

#### **2 Regional by direct extension only**

Extension to:

##### **All sites:**

Ampulla of Vater

Blood vessel(s) (major):

Hepatic artery

Portal vein

Superior mesenteric artery/vein

Duodenum

Extrahepatic bile duct(s)

Peripancreatic tissue, NOS

##### **Head of pancreas:**

Adjacent stomach

Blood vessel(s) (major):

Gastroduodenal artery

Pancreaticoduodenal artery

Body of stomach\*\*\*

Stomach, NOS

Transverse colon, including hepatic flexure

##### **Body and/or tail of pancreas:**

Blood vessel(s) (major):

Aortic artery

Celiac artery

Splenic artery/vein

Spleen

Splenic flexure

Stomach

Fixation to adjacent structures, NOS

**3 Regional lymph node(s) involved only**

REGIONAL Lymph Nodes

Celiac **for head only**

Hepatic

Infrapyloric (subpyloric) **for head only**

Lateral aortic (lumbar)

Pancreaticosplenic (pancreaticolienal) **for body and tail only**

Peripancreatic, NOS:

Anterior, NOS:

Anterior pancreaticoduodenal

Anterior proximal mesenteric

Pyloric

Inferior to the head and body of pancreas

Posterior, NOS:

Pericholedochal (common bile duct)

Posterior pancreaticoduodenal

Posterior proximal mesentery

Superior to the head and body of pancreas

Retroperitoneal

Splenic (lienal) **for body and tail only:**

Gastroepiploic (gastro-omental), left

Splenic hilum **for body and tail only**

Suprapancreatic **for body and tail only**

Superior mesenteric

Regional lymph node(s), NOS

**4 Regional by BOTH direct extension AND regional lymph node(s) involved**

Codes (2) + (3)

**5 Regional, NOS**

**Continued on next page**

## PANCREAS: HEAD, BODY, AND TAIL

C25.0-C25.4

### 7 Distant site(s)/node(s) involved

Distant lymph node(s)

Extension to:

#### All sites:

Gallbladder<sup>###\*\*</sup>

Liver including porta hepatis<sup>###\*\*</sup>

Mesenteric fat<sup>###\*\*</sup>

Mesentery<sup>###\*\*</sup>

Mesocolon<sup>###\*\*</sup>

Peritoneum<sup>###\*\*</sup>

#### Head of pancreas:

Adrenal

Adrenal (suprarenal) gland

Colon (other than transverse colon including hepatic flexure)

Ileum

Jejunum

Kidney

Omentum<sup>###\*\*</sup>

Retroperitoneum

Spleen

Ureter

#### Body and/or tail of pancreas:

Adrenal (suprarenal) gland<sup>\*\*</sup>

Adrenal, left<sup>###\*\*</sup>

Adrenal, right

Colon (other than splenic flexure)

Diaphragm

Ileum<sup>\*\*</sup>

Jejunum<sup>\*\*</sup>

Kidney

Kidney, left<sup>###\*\*</sup>

Kidney, right

Retroperitoneal soft tissue (retroperitoneal space)

Ureter, left<sup>###\*\*</sup>

Ureter, right

Further contiguous extension

Metastasis

### 9 Unknown if extension or metastasis

**Note:** Islets of Langerhans are distributed throughout the pancreas

**##** Considered regional in Historic Stage

**\*\*** Considered regional in 1977 Summary Staging Guide

**\*\*\*** Considered distant in 1977 Summary Staging Guide



**PANCREAS: OTHER AND UNSPECIFIED**

C25.7-C25.9

C25.7 Other and unspecified parts of pancreas (neck)

C25.8 Overlapping lesion of pancreas

C25.9 Pancreas, NOS

**SUMMARY STAGE**

**0 In situ:** Noninvasive; intraepithelial

**1 Localized only**

Invasive tumor confined to pancreas

Localized, NOS

**2 Regional by direct extension only**

Adjacent large vessel(s)

Ampulla of Vater

Colon

Duodenum

Extrahepatic bile duct(s)

Peripancreatic tissue

Spleen

Stomach

**3 Regional lymph node(s) involved only**

REGIONAL Lymph Nodes

Celiac  
Hepatic  
Infrapyloric (subpyloric)  
Lateral aortic (lumbar)  
Pancreaticosplenic (pancreaticolienal)  
Peripancreatic, NOS:  
    Anterior, NOS:  
        Anterior pancreaticoduodenal  
        Anterior proximal mesenteric  
        Pyloric  
    Inferior to the head and body of pancreas  
    Posterior, NOS:  
        Pericholedochal (common bile duct)  
        Posterior pancreaticoduodenal  
        Posterior proximal mesentery  
    Superior to the head and body of pancreas  
Retroperitoneal  
Splenic (lienal), NOS:  
    Gastroepiploic (gastro-omental), left  
    Splenic hilum  
    Suprapancreatic  
Superior mesenteric  
  
Regional lymph node(s), NOS

**4 Regional by BOTH direct extension AND regional lymph node(s) involved**

Codes (2) + (3)

**5 Regional, NOS**

**7 Distant site(s)/node(s) involved**

Distant lymph node(s)  
  
Further contiguous extension  
  
Metastasis

**9 Unknown if extension or metastasis**

## **OTHER AND ILL-DEFINED DIGESTIVE ORGANS**

C26.0, C26.8-C26.9

C26.0 Intestinal tract, NOS

C26.8 Overlapping lesion of digestive system

C26.9 Gastrointestinal tract, NOS

## **SUMMARY STAGE**

**0 In situ:** Noninvasive; intraepithelial

### **1 Localized only**

Invasion of submucosa

Localized, NOS

### **2 Regional by direct extension only**

Extension to:

Adjacent tissue(s), NOS

Connective tissue

*See definition of connective tissue on page 14.*

Adjacent organs/structures

*See definition of adjacent organs/structures on page 14.*

### **3 Regional lymph node(s) involved only**

REGIONAL Lymph Nodes

Intra-abdominal

Paracaval

Pelvic

Subdiaphragmatic

Regional lymph node(s), NOS

### **4 Regional by BOTH direct extension AND regional lymph node(s) involved**

Codes (2) + (3)

### **5 Regional, NOS**

### **7 Distant site(s)/lymph node(s) involved**

Distant lymph node(s)

Further contiguous extension

Metastasis

### **9 Unknown if extension or metastasis**

