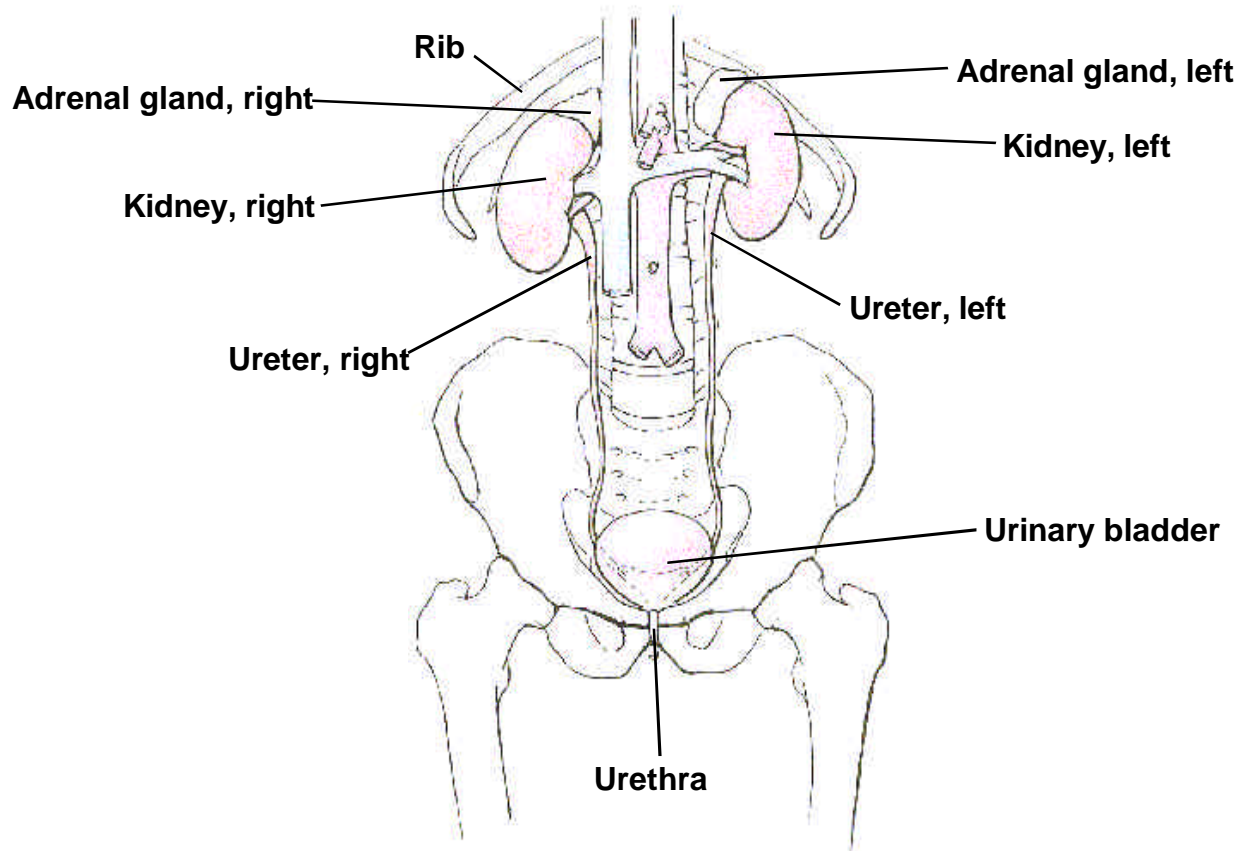


ANATOMIC DRAWING OF THE URINARY SYSTEM



THE URINARY SYSTEM

BLADDER, RENAL PELVIS, and URETERS

The mucosa of the urinary tract consists of:

The EPITHELIAL LAYER contains no blood vessels or lymphatics.

The BASEMENT MEMBRANE, a sheet of extracellular material, functions as a filtration barrier and a boundary involved in generating and maintaining tissue structure.

The LAMINA PROPRIA, composed of areolar connective tissue, contains blood vessels, nerves, and, in some regions, glands. Once tumor has broken through the basement membrane into the lamina propria, it can spread by way of the lymphatics and blood vessels to other parts of the body.

The urinary sites do NOT have a MUSCULARIS MUCOSAE, and, therefore, the lamina propria and the submucosa are difficult to separate. These terms are used interchangeably.

The SUBMUCOSA is a thick layer of either dense or areolar connective tissue. It contains blood vessels, lymphatic vessels, nerves, and, in some regions, glands.

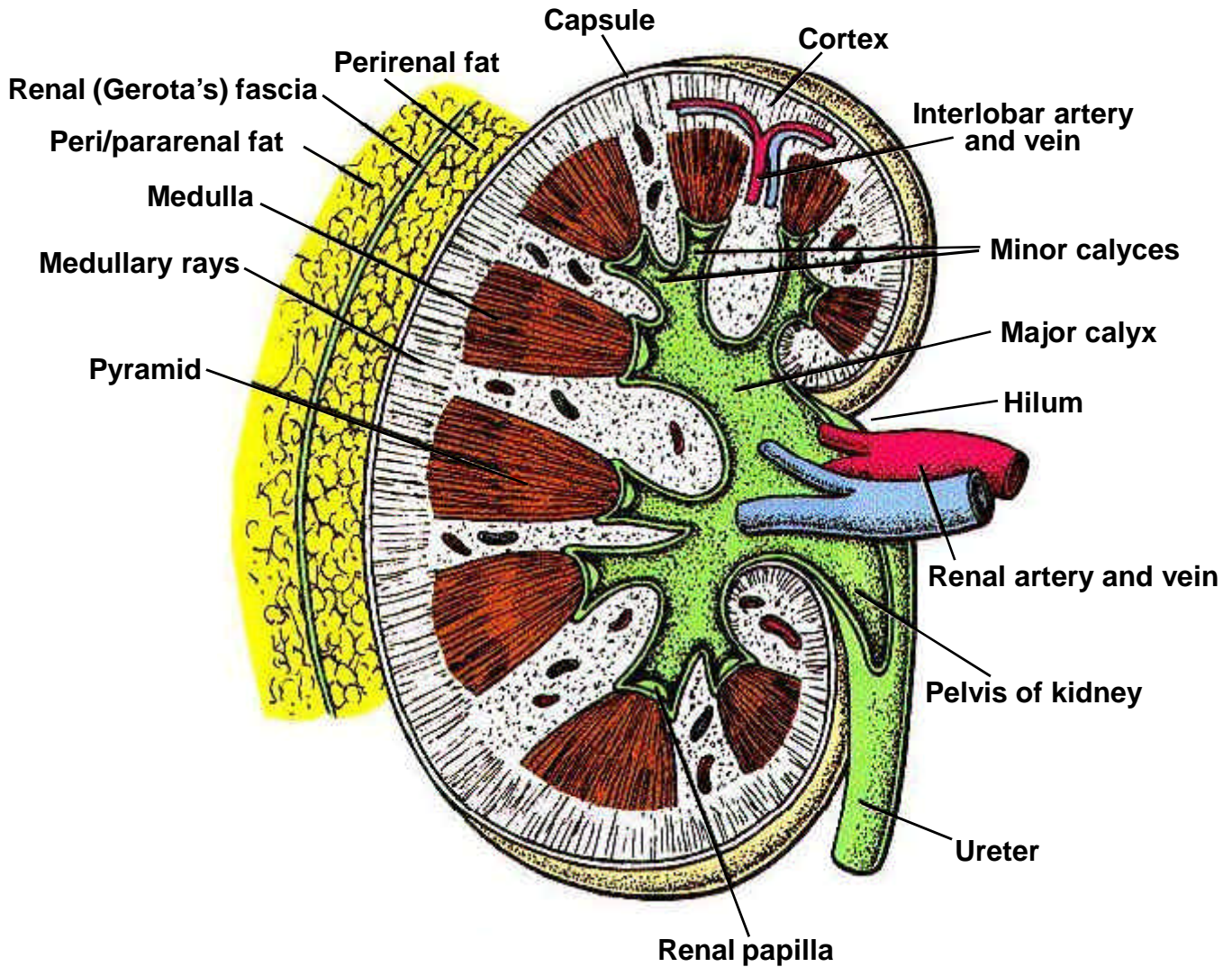
The MUSCULARIS PROPRIA is composed of multiple layers of muscle tissue; it constitutes the wall of the organ.

The SEROSA, the outermost layer covering, is a serous membrane, part of the visceral peritoneum. It covers only the superior surface of the bladder. There is no serosa on the renal pelvis or ureters. Where there is no serosa, the connective tissue of surrounding structures merges with the connective tissue of the urinary organs and is called ADVENTITIA.

**BLADDER, RENAL, PELVIS and URETERS
TABLE OF ANATOMIC STRUCTURES**

PRIMARY SITE	MUSCOSA		MUSCULARIS PROPRIA	SEROSA
	Epithelium	B A S E M E N T M E M B R A N E		
Bladder (C67.~)	Yes	Lamina Propria Submucosa Yes	Yes	Yes, on superior surface
Renal pelvis (C65.9)	Yes	Yes	Yes	No
Ureter(s) (C66.9)	Yes	Yes	Yes	No

ANATOMIC DRAWING OF THE KIDNEY AND RENAL PELVIS



CROSS SECTION OF THE KIDNEY

KIDNEY (Renal) PARENCHYMA

C64.9

C64.9 Kidney, NOS (Kidney parenchyma) <>

<> Laterality must be coded for this site.

SUMMARY STAGE

0 In situ: Noninvasive; intraepithelial

1 Localized only

Invasive cancer confined to kidney cortex and/or medulla

Invasion of renal capsule

Renal pelvis or calyces involved

Separate focus of tumor in renal pelvis/calyx

Localized, NOS

2 Regional by direct extension only

Extension to:

Adrenal (suprarenal) gland, ipsilateral

Ascending colon **from right kidney**

Blood vessel(s) (major):

Extrarenal portion of renal vein

Hilar blood vessel

Perirenal vein

Renal artery

Renal vein, NOS

Tumor thrombus in a renal vein, NOS

Vena cava

Descending colon **from left kidney**

Diaphragm

Duodenum **from right kidney**

Perirenal (perinephric) tissue/fat

Peritoneum

Psoas muscle ***

Renal (Gerota's) fascia

Retroperitoneal soft tissue

Tail of pancreas

Ureter, including implant(s), ipsilateral

3 Regional lymph node(s) involved only

REGIONAL Lymph Nodes (including contralateral and bilateral)

Aortic, NOS###:
Lateral (lumbar)
Para-aortic
Periaortic
Paracaval####**
Renal hilar
Retroperitoneal, NOS###

Regional lymph node(s), NOS

4 Regional by BOTH direct extension AND regional lymph node(s) involved

Codes (2) + (3)

5 Regional, NOS

7 Distant site(s)/lymph node(s) involved

Distant lymph node(s)

Further contiguous extension:

Aorta
Contralateral:
Adrenal (suprarenal) gland
Kidney
Ureter

Liver
Ribs##
Spleen
Stomach

Other direct extension

Metastasis

9 Unknown if extension or metastasis

Note: The parenchyma of the kidney includes the following structures: cortex (outer layer of kidney) and renal columns; medulla, medullary rays, renal pyramids, and renal papillae; nephrons (renal corpuscle, loops of Henle, proximal and distal tubules, collecting duct), glomerulus, and Bowman's capsule. The most common site for renal parenchymal cancer to develop is in the proximal convoluted tubule. Tumor extension from one of these structures into another would be coded to **localized** unless there were further signs of involvement.

Considered regional in Historic Stage

Considered distant in Historic Stage

** Considered distant in 1977 Summary Staging Guide

RENAL PELVIS AND URETER

C65.9, C66.9

C65.9 Renal pelvis <>

C66.9 Ureter <>

<> Laterality must be coded for this site.

SUMMARY STAGE

0 In situ: Noninvasive; intraepithelial

Carcinoma in situ, NOS

Papillary noninvasive carcinoma

1 Localized only

Muscularis invaded

Subepithelial connective tissue (lamina propria, submucosa) invaded

Localized, NOS

2 Regional by direct extension only

Extension to:

Adjacent tissue(s), NOS:

Connective tissue

Peripelvic/periureteric tissue

Retroperitoneal soft/connective tissue

Adrenal (suprarenal) gland **from renal pelvis**###

Bladder **from ureter**

Blood vessel(s) (major):###

Aorta

Renal artery/vein

Tumor thrombus in a renal vein, NOS

Vena cava (inferior)

Duodenum **from right renal pelvis or right ureter**###

Implants in ureter

Ipsilateral kidney parenchyma and kidney, NOS **from renal pelvis**

Psoas muscle **from ureter**

Ureter **from renal pelvis**

3 Regional lymph node(s) involved only

REGIONAL Lymph Nodes (including contralateral and bilateral)

Renal Pelvis:

Aortic, NOS###:

Lateral (lumbar)

Para-aortic

Periaortic

Paracaval

Renal hilar

Retroperitoneal, NOS

Regional lymph node(s), NOS

Ureter:

Iliac, NOS:

Common

External

Internal (hypogastric), NOS:

Obturator

Lateral aortic (lumbar)

Paracaval

Pelvic, NOS

Periureteral

Renal hilar

Retroperitoneal, NOS

Regional lymph node(s), NOS

4 Regional by BOTH direct extension AND regional lymph node(s) involved

Codes (2) + (3)

5 Regional, NOS

RENAL PELVIS AND URETER

C65.9, C66.9

7 Distant site(s)/lymph node(s) involved

Distant lymph node(s)

Extension to^{##}:

- Ascending colon
- Bladder (wall or mucosa) **from renal pelvis**
- Colon, NOS
- Descending colon
- Ipsilateral kidney parenchyma **from ureter**
- Liver
- Pancreas
- Perirenal (perinephric) fat via kidney
- Spleen

Further contiguous extension

Ureter:

- Prostate
- Uterus

Other direct extension

Metastasis

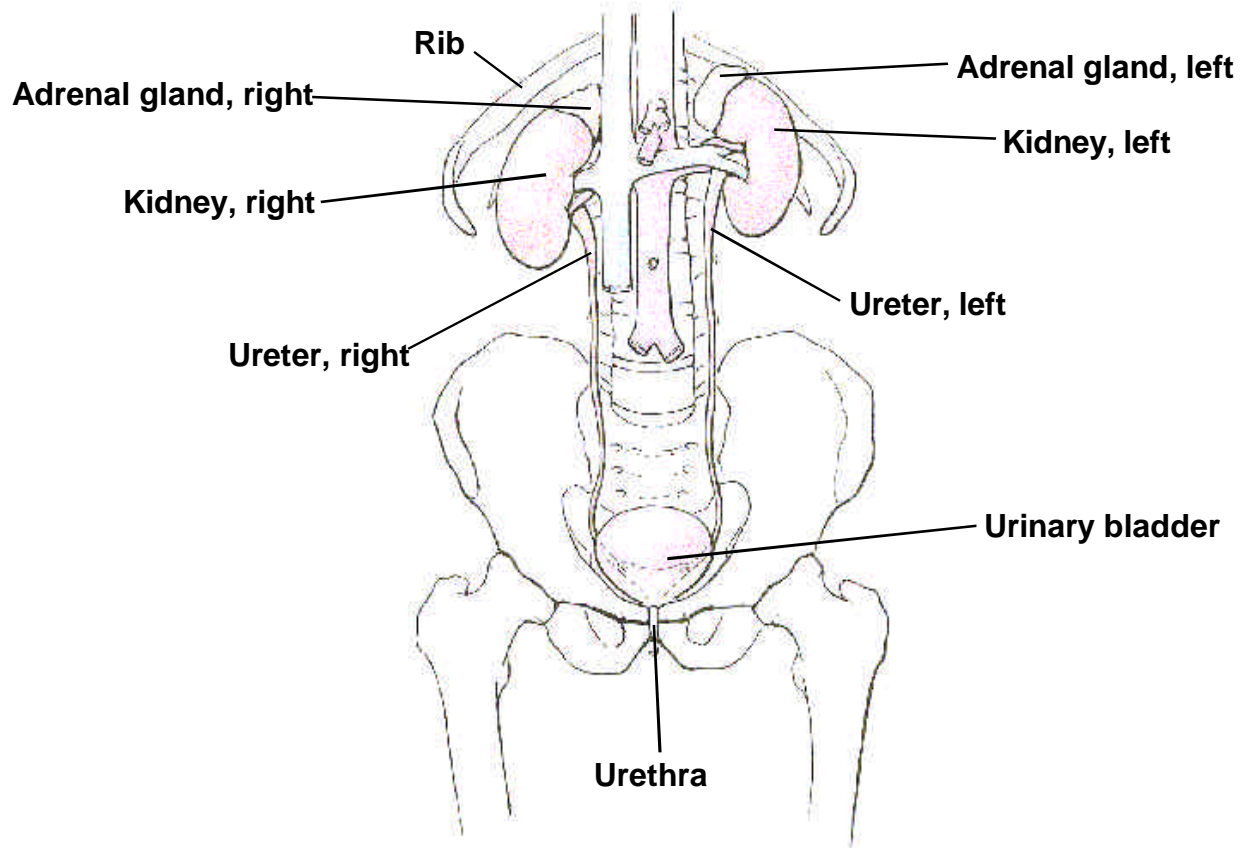
9 Unknown if extension or metastasis

Note: Ascending colon from right ureter and descending colon from left ureter considered Regional in 1977 Summary Stage.

^{##} Considered regional in Historic Stage

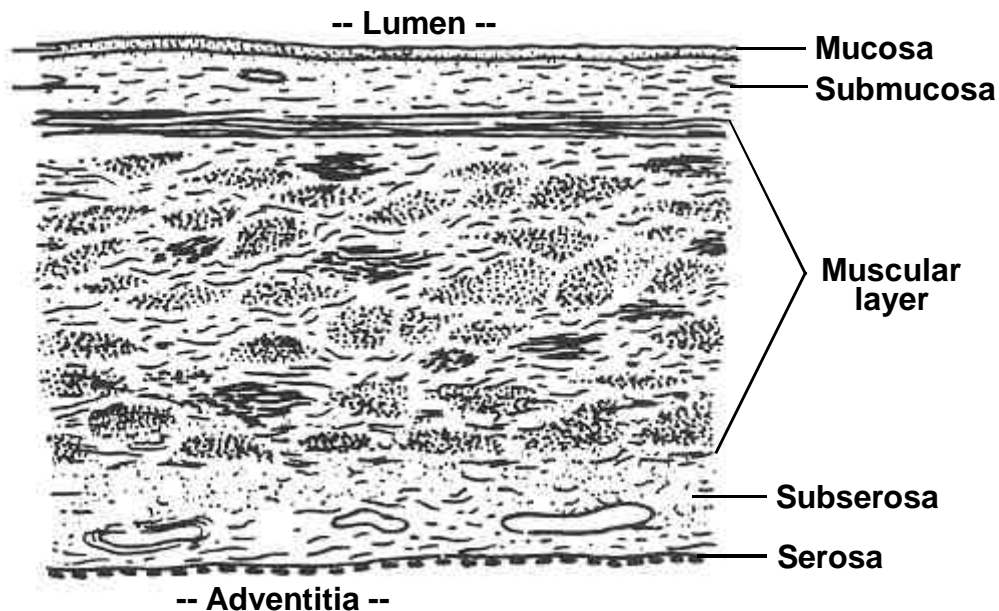
^{###} Considered distant in Historic Stage

ANATOMIC DRAWINGS OF THE BLADDER

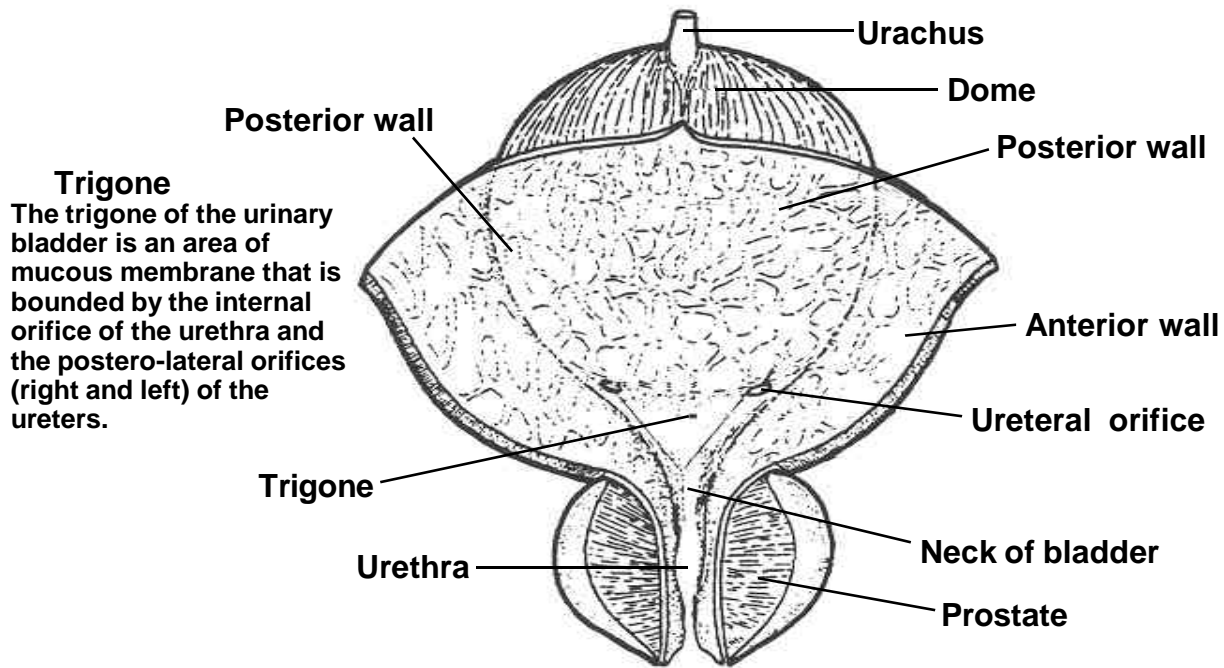


THE URINARY SYSTEM

ANATOMIC DRAWINGS OF THE BLADDER



BLADDER WALL



BLADDER AND PROSTATE
(bladder and prostate are cut open)

DISTINGUISHING NONINVASIVE AND INVASIVE BLADDER CANCER

The two main types of bladder cancer are the flat (sessile) variety and the papillary type. Only the flat (sessile) variety is called in situ when tumor has not penetrated the basement membrane. Papillary tumor that has not penetrated the basement membrane is called noninvasive, and pathologists use many different descriptive terms for noninvasive papillary transitional cell carcinoma. Frequently, the pathology report does not contain a definite statement of noninvasion; however, noninvasion can be inferred from the microscopic description. The more commonly used descriptions for noninvasion are listed below.

Careful attention must be given to the use of the term “confined to mucosa” for bladder. Historically, carcinomas described as “confined to mucosa” were coded as localized. However, pathologists use this designation for noninvasion as well. In order to rule out the possibility of coding noninvasive tumors in this category, abstractors should determine:

- 1) If the tumor is confined to the epithelium, then it is noninvasive.
- 2) If the tumor has penetrated the basement membrane to invade the lamina propria, then it is invasive. The terms lamina propria, submucosa, stroma, and subepithelial connective tissue are used interchangeably.
- 3) Only if this distinction cannot be made should the tumor be coded to “confined to mucosa.”

For Bladder Cases Only

Definite Statements of Noninvasion

Non-infiltrating; noninvasive
No evidence of invasion
No extension into lamina propria
No stromal invasion
No extension into underlying supporting tissue
Negative lamina propria and superficial muscle
Negative muscle and (subepithelial) connective tissue
No infiltrative behavior/component

For Bladder Cases Only

Inferred Description of Noninvasion

No involvement of muscularis propria and no mention of subepithelium/submucosa
No statement of invasion (microscopic description present)
(Underlying) Tissue insufficient to judge depth of invasion
No invasion of bladder wall; no involvement of muscularis propria
Benign deeper tissue
Microscopic description problematic for pathologist
(noninvasion versus superficial invasion)
Froned surfaced by transitional cells
No mural infiltration
No evidence of invasion (no sampled stroma)

BLADDER

C67.0-C67.9

C67.0 Trigone of bladder

C67.1 Dome of bladder

C67.2 Lateral wall of bladder

C67.3 Anterior wall of bladder

C67.4 Posterior wall of bladder

C67.5 Bladder neck

C67.6 Ureteric orifice

C67.7 Urachus

C67.8 Overlapping lesion of bladder

C67.9 Bladder, NOS

SUMMARY STAGE

0 In situ: Noninvasive; intraepithelial

Carcinoma in situ, NOS

Noninvasive papillary (transitional) cell carcinoma

Papillary non-infiltrating

Papillary transitional cell carcinoma, stated to be noninvasive

Papillary transitional cell carcinoma, with inferred description of noninvasion

Sessile (flat) (solid) carcinoma in situ

Transitional cell carcinoma in situ

Jewett-Strong-Marshall Stage 0

TNM/AJCC Ta

Jewett-Strong-Marshall CIS

TNM/AJCC Tis

1 Localized only

Invasive tumor confined to:

Mucosa, NOS

Muscle (muscularis)^{##}:

Deep muscle—outer half

Extension through full thickness of bladder wall

Superficial muscle—inner half

NOS

Submucosa:

Lamina propria

Stroma

Subepithelial connective tissue

Tunica propria

Subserosa

Jewett-Strong-Marshall Stage A

TNM/AJCC T1, T2

Localized, NOS

2 Regional by direct extension only

Bladder FIXED

Extension to:

- Adventitia
- Extravesical mass
- Parametrium
- Periprostatic tissue
- Peritoneum
- Periureteral fat/tissue
- Perivesical fat/tissue
- Prostate
- Rectovesical/Denonvilliers' fascia
- Seminal vesicle
- Serosa (mesothelium) (to/through)
- Tunica serosa (to/through)
- Ureter
- Urethra (including prostatic urethra)
- Uterus
- Vagina
- Vas deferens

3 Regional lymph node(s) involved only

REGIONAL Lymph Nodes (including contralateral and bilateral)

Iliac, NOS:

- External

- Internal (hypogastric), NOS:

- Obturator

Pelvic, NOS

Perivesical

Sacral, NOS###:

- Lateral (laterosacral)

- Middle (promontorial) (Gerota's node)

- Presacral

Regional lymph node(s), NOS

4 Regional by BOTH direct extension AND regional lymph node(s) involved

Codes (2) + (3)

5 Regional, NOS

BLADDER

C67.0-C67.9

7 Distant site(s)/lymph node(s) involved

Distant lymph node(s):

Common iliac^{**}

Other distant lymph node(s)

Extension to:

Abdominal wall

Bone

Colon

Pelvic wall

Rectum

Further contiguous extension

Metastasis

9 Unknown if extension or metastasis

Note 1: The lamina propria and submucosa tend to merge when there is no muscularis mucosae, so these terms may be used interchangeably.

Note 2: The meaning of the terms “invasion of mucosa, grade 1” and “invasion of mucosa, grade 2” varies with the pathologist, who must be queried to determine whether the carcinoma is “noninvasive” or “invasive.”

Note 3: Statements Meaning Confined to Mucosa, NOS

Confined to mucosal surface

Limited to mucosa, no invasion of submucosa and muscularis

No infiltration/invasion of fibromuscular and muscular stroma

Superficial, NOS

Note 4: Pubic bone and rectum for males are considered regional by direct extension in the 1977 Summary Staging Guide. For males, non-prostatic urethra considered to be distant in 1977 Summary Staging Guide.

Considered regional in Historic Stage

Considered distant in Historic Stage

** Considered regional in 1977 Summary Staging Guide

*** Considered distant in 1977 Summary Staging Guide

URETHRA, PARAURETHRAL GLAND, AND UNSPECIFIED URINARY ORGANS

C68.0-C68.1, C68.8-C68.9

C68.0 Urethra (including transitional cell carcinoma of prostatic urethra {M8120-8130})

C68.1 Paraurethral gland

C68.8 Overlapping lesion of urinary organs

C68.9 Urinary system, NOS

SUMMARY STAGE

0 In situ: Noninvasive; intraepithelial

Carcinoma in situ, NOS

Noninvasive papillary, polypoid, or verrucous carcinoma

1 Localized only

Muscularis invaded

Subepithelial connective tissue (lamina propria, submucosa) invaded

Localized, NOS

2 Regional by direct extension only

Extension beyond the prostatic capsule

Extension to:

Bladder neck

Corpus cavernosum

Corpus spongiosum

Periurethral muscle (sphincter)

Prostate

Vagina, anterior or NOS

3 Regional lymph node(s) involved only

REGIONAL Lymph Nodes (including contralateral and bilateral)

Iliac, NOS:

Common

External

Internal (hypogastric), NOS:

Obturator

Inguinal, NOS:

Deep, NOS:

Node of Cloquet or Rosenmuller (highest deep inguinal)

Superficial (femoral)

Pelvic, NOS

Presacral

Sacral, NOS

Regional lymph node(s), NOS

URETHRA, PARAURETHRAL GLAND, AND UNSPECIFIED URINARY ORGANS
C68.0-C68.1, C68.8-C68.9

4 Regional by BOTH direct extension AND regional lymph node(s) involved

Codes (2) + (3)

5 Regional, NOS

7 Distant site(s)/lymph node(s) involved

Distant lymph node(s)

Extension to:

Bladder (excluding bladder neck)^{##}

Seminal vesicle(s)^{##}

Other adjacent organs^{##}

Further contiguous extension

Metastasis

9 Unknown if extension or metastasis

Note: Transitional cell carcinoma (M-8120-8130) of the prostatic ducts and prostatic urethra are to be coded to urethra (C68.0) and Summary Stage assigned according to this scheme.

^{##} Considered regional in Historic Stage