

Chapter 13

Aspergillosis

Synonyms

Brooder pneumonia, pseudotuberculosis, "asper" mycosis, mycotic pneumonia

Cause

Aspergillosis is a respiratory tract infection caused by fungi of the genus *Aspergillus*, of which *A. fumigatus* is the primary species responsible for infections in wild birds (Fig. 13.1). Aspergillosis is not contagious (it will not spread from bird to bird), and it may be an acute, rapidly fatal disease or a more chronic disease. Both forms of the disease are commonly seen in free-ranging birds, but the acute form is generally responsible for large-scale mortality events in adult birds and for brooder pneumonia in hatching birds. *Aspergillus* sp. also produce aflatoxins (see Chapter 37, Mycotoxins), but the significance of those toxins in the ability of the fungus to cause disease in birds is unknown.

Aspergilli are saprophytic (live upon dead or decaying organic matter) molds that are closely associated with agriculture and other human activities that make nutrients available to fungi. *A. fumigatus* commonly grows in damp soils, decaying vegetation, organic debris, and feed grains. High numbers of spores (called conidia) are released into the atmosphere and are inhaled by humans, birds, and other animals. These spores travel through the upper respiratory tract to the lungs. If the spores colonize the lungs, then the fungi may be disseminated to other parts of the body and disease, often leading to death, occurs.

Acute aspergillosis has caused devastating loss of birds in hatcheries. The source of infection in some instances has been contaminated litter. Also, infection of broken eggs prior to hatching provides an ideal growth medium for the fungus and the subsequent production of massive numbers of spores for infection of newly hatched birds. Inhaled spores initiate a cellular response in the lungs that results in the air passages soon becoming obliterated by cellular material and branching fungal filaments. Asphyxiation quickly follows and causes death. Acute aspergillosis has also been found in free-ranging waterfowl. The circumstances of these events are uniformly associated with birds feeding in waste grain and in silage pits during inclement weather. The mallard duck has been the primary species involved, and the events have only lasted a few days, terminating when the weather improved and allowed the ducks to resume normal feeding. Field investigations of several events disclosed heavily contaminated feed that resulted in overwhelming exposure to *A. fumigatus* (Fig. 13.2).

Chronic forms of aspergillosis have been described in wild birds since at least 1813. Typically, the lungs and air sacs are chronically infected, resulting in a gradual reduction in respiratory function. Eventual dissemination of the fungus to the liver, gut wall, and viscera is facilitated by infection of the extensive system of air sacs that are part of the avian respiratory system.

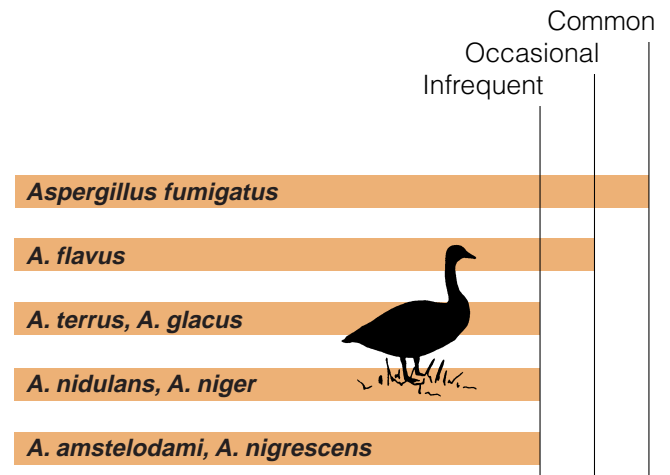


Figure 13.1 Primary causes of aspergillosis in birds.



Figure 13.2 Moldy grain pile that was the source of acute aspergillosis in wild waterfowl.

Species Affected

A wide variety of birds have died of aspergillosis and probably all birds are susceptible to it. Aspergillosis was one of the first diseases described for wild birds; it was noted in a scaup in 1813 and in a European jay in 1815. Loons and marine birds that are brought into rehabilitation, captive raptors, and penguins being maintained in zoological parks and other facilities commonly die from aspergillosis. This disease also develops at birdfeeding stations and it causes waterfowl die-offs. Young birds appear to be much more susceptible than adults. Most reported mortalities of free-ranging wild birds involve isolated mortalities found during post-mortem evaluations rather than mortalities found during major die-offs (Fig. 13.3).

Distribution

Aspergillosis in birds is reported nearly worldwide.










Seasonality

Most aspergillosis outbreaks in waterfowl happen in fall to early winter; individual cases can occur at any time, particularly among birds stressed by crippling, oiling, malnutrition, recent capture, and concurrent disease conditions. This disease can cause serious losses among seabirds in rehabilitation programs after oil spills. Aspergillosis is a frequent complication in hunter-crippled waterfowl, among birds on nutritionally deficient diets, and in Canada geese whose immune systems have been compromised by exposure to environmental contaminants such as lead.

Environmental factors also contribute to the time of year when aspergillosis is seen. Scattered outbreaks of this disease occurred among American coot, diving ducks, tundra swan, and passerine birds throughout California one winter at the end of a 3-year drought. Severe dust conditions associated with this weather pattern are thought to have interfered with respiratory clearance mechanisms by reducing the amount of mucous and other body secretions that coat the cellular lining of the throat and air passages to the lungs, thereby increasing bird susceptibility to aspergillosis. A fall outbreak in Steller's jays in British Columbia was associated with a particularly dry and warm summer.

Brooder pneumonia, a specialized springtime form of aspergillosis, infects chicks or ducklings that are placed in *Aspergillus*-contaminated brooders. Catastrophic losses have occurred on game farms under these circumstances. Chicks have also been lost during captive-rearing of endangered species. Aspergillosis is also an important cause of mortality in winter roosts of blackbirds in Maryland and Pennsylvania.

Figure 13.3 Relative occurrence of aspergillosis in free-ranging wild birds.

		Rare or not reported	Infrequent	Occasional	Common
Waterfowl					
Gulls					
Crows, raven					
Raptors					
	(free-living)				
	(captive)				
					
Songbirds					
Upland gamebirds					
Blackbirds, cowbirds, grackles					
Herons					
Shorebirds					

Field Signs

The typical aspergillosis-affected bird is emaciated, and it frequently exhibits severe and progressive difficulty in breathing by gaping or rapid opening and closing of the bill (Fig. 13.4A). Birds often appear to be unthrifty, and their wings may droop (Fig. 13.4B). Infected birds are usually weak and may fail to try to escape. With the exception of visible evidence of breathing difficulties, these signs are similar to those for lead poisoning. Infection that reaches the brain can result in obvious loss of muscular coordination and twisting of the head and neck so that the head is held in unnatural positions. Inflammation of the covering of the brain or meningoencephalitis with associated areas of brain tissue death has been reported for eider ducklings dying from aspergillosis.

Epizootic aspergillosis and brooder pneumonia outbreaks are often characterized by sudden deaths of previously healthy birds. Sick birds show acute respiratory distress and failure.



Figure 13.4 (A) Respiratory distress and gaping (note the open bill) in a herring gull suffering from aspergillosis. (B) Wing droop also occurs. Note that the wing on the near side of this bird is drooping well below the body.

Gross Lesions

Birds infected with the more typical chronic form of aspergillosis usually have variously sized lesions in their lungs and air sacs. Typically, these lesions appear as flattened, yellow plaques with a cheesy appearance and consistency (Fig. 13.5). Continuous masses of these lesions may completely line the air sac. There may also be an extensive fungus growth on tissue and air sac surfaces that appears similar to bread mold. This velvety, blue-green or grey fungal mat is striking in appearance (Fig. 13.6).

In cases of acute aspergillosis, the birds are usually in good flesh and have good-to-moderate deposits of fat. Air sacs are usually thickened, but the most striking lesion is a dark red, firm lung that is often studded or peppered with small, 1–2 millimeter, yellow nodules (Fig. 13.7).

Other, less common lesions that have been described include necrotic skin granulomas or semifirm growths of granular consistency in chickens and pigeons. Cheesy plaques that form in the eye beneath the nictitating membrane, which is the transparent membrane that forms a rapidly moving third eyelid that keeps the eye clean and moist, or on the surface of the eye have also been observed.

Diagnosis

Whole carcasses should be submitted for necropsy by qualified diagnosticians. Diagnosis is based on finding the typical lesions and on isolating the fungus from the tissues. *Aspergillus* sp. can be identified by microscopically examining material from fungal mats and from tissue sections that have been specially stained. However, the specific species of *Aspergillus* cannot be identified by these means.

Control

The spores of the mold *A. fumigatus* are widely distributed and are often present in moldy feeds, unclean brooders and incubators, moldy straw, and rotting agricultural waste. *Aspergillus* grows best on decomposing organic matter left in a warm, dark, moist environment. Failure to maintain a clean environment often leads to severe outbreaks.

Aspergillosis has broken out in mallards feeding in fields that were previously covered by discarded moldy corn and silage. Dusty straw placed as litter in the bottoms of wood duck nest boxes has resulted in losses of wood duck ducklings. Avoid using moldy or dusty straw, silage, or feed, and dumping moldy waste grain in areas where waterfowl and other birds feed. Birds should be denied the use of fields where moldy agricultural waste products such as waste corn, peanuts, straw, or hay have accumulated. Monitoring for such situations in waterfowl concentration areas and establishing contingency plans that can be implemented at the onset of inclement weather can minimize the potential for waterfowl deaths if the concentrated sources of *Aspergillus* spores can not be dealt with in other ways. People who feed birds should be educated to periodically clean their feeding stations.

Photos by Milton Friend

Figure 13.5 “Cheesy” plaques in the lungs and air sacs of a bird with aspergillosis.

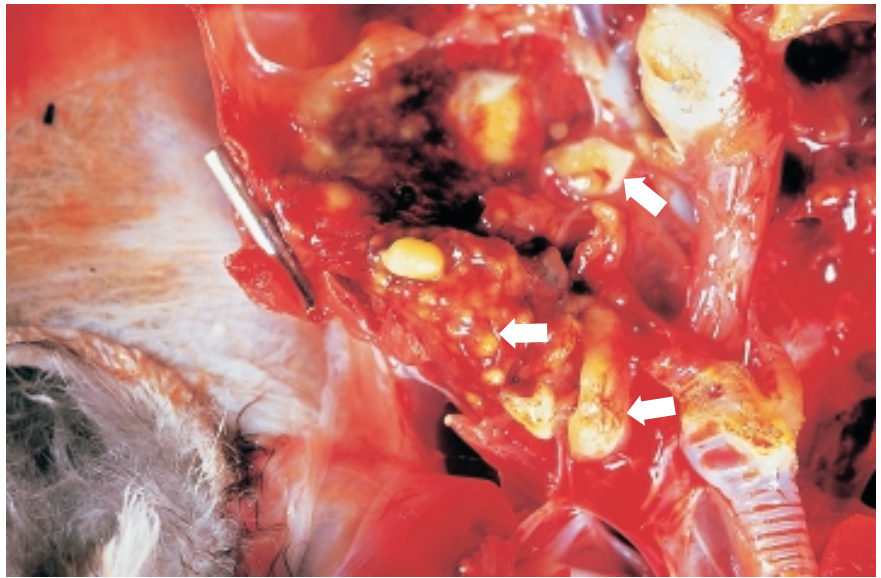
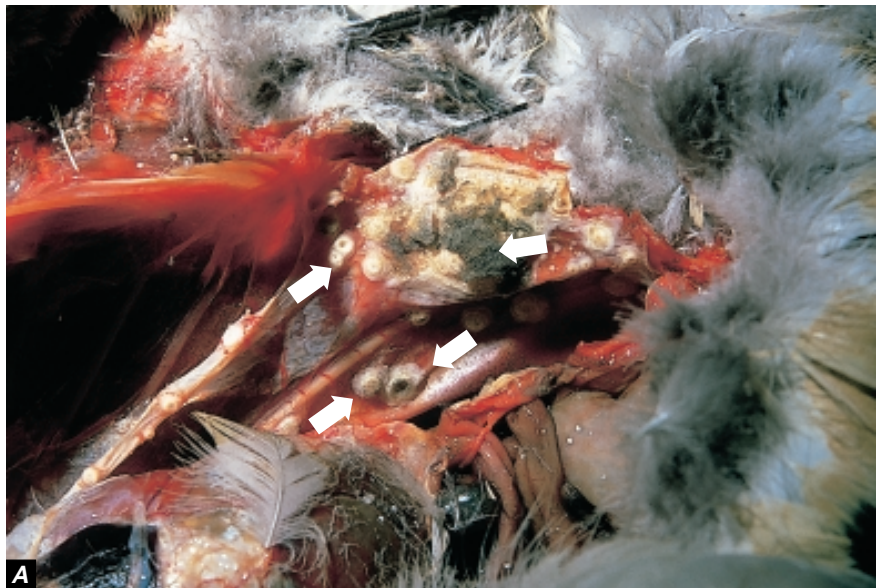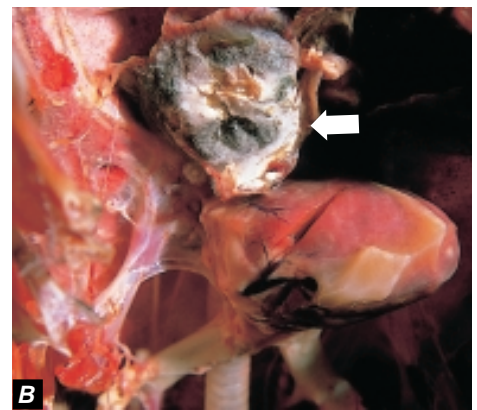


Photo by Milton Friend



A

Figure 13.6 Lung of a bird with chronic aspergillosis showing (A) “cheesy” fungal plaques, and (B) “bread mold” fungal mat totally involving the air sac adjacent to the heart of this bird.



B

Photos by Milton Friend

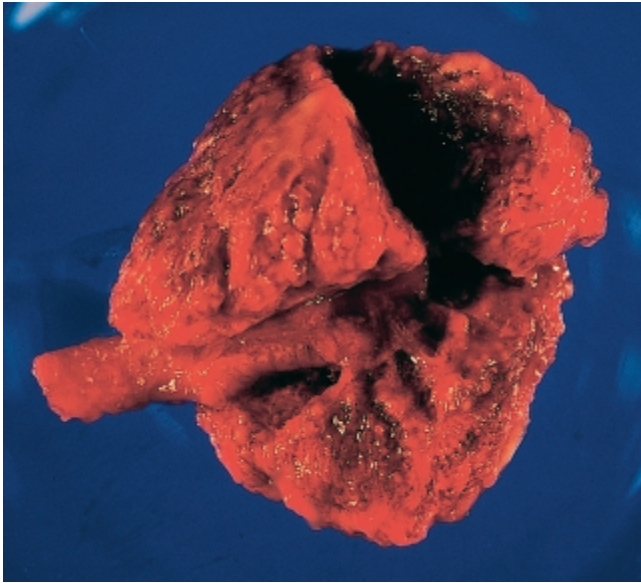


Photo by James Runnigen

Figure 13.7 Acute aspergillosis or “brooder pneumonia” in a lung of a wood duck duckling. Note dark red, “studded” (granular) appearance of lung.

Human Health Considerations

Aspergillosis is not contagious. However, when human resistance to infection is impaired, aspergilli can cause rapidly developing acute infection following environmental exposure. Invasive aspergillosis in humans involving dissemination of fungi to organs other than the lungs is often associated with the person being immunocompromised and, if the disease is not properly diagnosed, it may be life threatening. A few individuals who have worked with *A. fumigatus* have become allergic to it. Allergic response can result in an acute, life-threatening reaction to this fungus. It is unlikely that infected bird carcasses would provide sufficient exposure to result in either of these outcomes.

Milton Friend

Supplementary Reading

- Adrian, W.J., Spraker, T.R., and Davies, R.B., 1978, Epornitics of aspergillosis in mallards (*Anas platyrhynchos*) in north central Colorado: *Journal of Wildlife Diseases*, v.14, p. 212–217.
- Barden, E.S., Chute, H.L., O’Meara, D.C., and Wheelwright, H.T., 1971, A bibliography of avian mycosis (partially annotated): Orono, Me., College of Life Sciences and Agriculture. Univ. of Maine, 193 p.
- O’Meara, D.C., and Witter, J.F., 1971, Aspergillosis, in Davis, J.W., and others, eds., *Infectious and parasitic diseases of wild birds*: Ames, Iowa, Iowa State University Press, p. 153–162.
- Powell, K.A., Renwick, A. and Peberdy, J.F., 1994, *The genus Aspergillus from taxonomy and genetics to industrial application*: Plenum Press, New York, N.Y., 380 p.
- Wobeser, G.A., 1997, Aspergillosis, in *Diseases of wild waterfowl* (2nd ed): New York, N.Y., Plenum Press, p. 95–101.

